


Damage control surgery in a patient with cardiac arrest from necrotizing soft tissue infection

Jianshe Shi ^{1,2}, Jialong Zheng,^{1,2} Yong Zhang,³ Yijie Chen,^{1,2} Chenghua Zhang^{1,2}

¹Surgical Intensive Care Unit, Huaqiao University Affiliated Strait Hospital, Quanzhou, Fujian, China

²Department of General Surgery, Huaqiao University Affiliated Strait Hospital, Quanzhou, Fujian, China

³Department of Burn and Plastic Surgery, Huaqiao University Affiliated Strait Hospital, Quanzhou, Fujian, China

Correspondence to

Dr Jianshe Shi; jianshe.shi@ocibe.com

Dr Yijie Chen; yijie.chen@ocibe.com

Dr Chenghua Zhang; ZCH180@163.com

Received 21 February 2024

Accepted 6 October 2024

CASE PRESENTATION

A man aged 53 years with uncontrolled type 2 diabetes was referred to our hospital in deteriorating condition following incision and drainage surgery for a perianal abscess. He developed delirium, high fever, tachycardia, tachypnea, hypotension, and oliguria. Examination revealed blackening and swelling in the scrotal and perineum regions, accompanied by mottled skin on the abdomen (figure 1). Key laboratory markers contributed to a Laboratory Risk Indicator for Necrotizing Fasciitis score of 11 and a Sequential Organ Failure Assessment score of 16 (table 1 and table 2). CT scans demonstrated the presence of gas within the scrotum, pararectal fascia, and bilateral abdominal walls (figure 2).

DIAGNOSIS

The patient was diagnosed with necrotizing soft tissue infection (NSTI) caused by a polymicrobial infection; the condition progressed to septic shock and multiple organ failure.

MANAGEMENT

Immediate fluid resuscitation was performed and broad-spectrum antibiotics (meropenem, linezolid, and clindamycin) were administered, followed by emergency surgery. However, approximately 20 min after debridement began, the patient experienced cardiac arrest and was resuscitated.

WHAT WOULD YOU DO NEXT?

1. Continue extensive and thorough debridement despite septic shock, multiple organ failure, and post-cardiopulmonary resuscitation
2. Recommend end-of-life care to the patient's family based on the poor prognosis.
3. Opt for damage control surgery by limiting the initial debridement and placing drainage tubes, while prioritizing patient stabilization before undertaking further surgical interventions.

WHAT WE DID AND WHY

To control sepsis, all infected necrotic tissue must be removed.¹ However, considering the patient's condition, additional surgical trauma and anesthesia could precipitate another cardiac arrest.² Therefore, we performed damage control surgery, suspending the debridement and inserting multiple dual-lumen tube suction and sump drains. The patient was transferred to the surgical intensive care unit (SICU) for further supportive organ management. Norepinephrine was administered (2.67 µg/kg/min) with fluid resuscitation guided by pulse indicator continuous cardiac output technology to maintain a

mean arterial pressure of ≥ 65 mm Hg. Mechanical ventilation with a positive end-expiratory pressure of 16 cm H₂O was used to maintain a PaO₂ above 80 mm Hg. Continuous renal replacement therapy was used to clear the inflammatory mediators.

Meanwhile, 1.5% hydrogen peroxide and saline were used for irrigation and suction in the dual-lumen tubes. Due to ongoing circulatory, respiratory, and renal failures, as well as thrombocytopenia, bedside stage debridement was restricted to control the sepsis source. On the fourth day after the initial surgery, norepinephrine administration was discontinued, with decreased lactate (from 12.8 mmol/L to 5.4 mmol/L) and proBNP (from 33 370 pg/mL to 11 781 pg/mL) levels. The reduction in extravascular lung water and improved lung compliance contributed to an oxygenation index of 340. The platelet transfusion increased platelet levels (from $5 \times 10^9/L$ to $40 \times 10^9/L$), and further debridement was performed in the operating room on the same day. However, owing to the extensive debridement area and wound surface oozing, thorough debridement was not achieved. On the seventh day, the rise in platelet count ($52 \times 10^9/L$) facilitated thorough debridement surgeries (figure 3) combined with negative-pressure devices. The patient developed ventilator dependency due to diaphragmatic dysfunction, leading to a tracheotomy on the 16th hospital day. By the 18th day, the patient regained consciousness and was transferred out of the SICU. Finally, the patient was discharged after two skin grafts on the 59th day.

DISCUSSION

Diabetes greatly increases NSTI risk.³ In this case, uncontrolled diabetes led to a perianal abscess rapidly evolving into Fournier's gangrene and extending to bilateral abdominal walls. On being referred to our hospital, the patient was experiencing septic shock, which is the most frequent cause of death associated with Fournier's gangrene.⁴

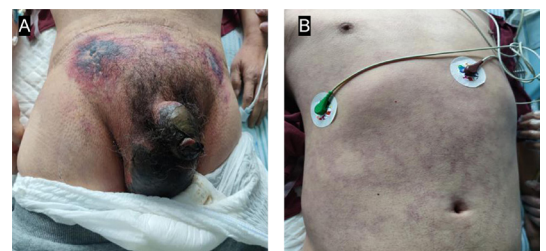

Figure 1 Blackening and swelling in the scrotal and perineum regions (panel A), abdominal skin mottling (panel B).

© Author(s) (or their employer(s)) 2024. Re-use permitted under CC BY-NC. No commercial re-use. See rights and permissions. Published by BMJ.

To cite:

Shi J, Zheng J, Zhang Y, et al. *Trauma Surg Acute Care Open* 2024;**9**:e001428.

Table 1 Laboratory Risk Indicator for Necrotizing Fasciitis score

Variables, units	Results	Score
C reactive protein, mg/L	383	4
Total white cell count, 10 ⁹ /L	25.53	2
Hemoglobin, g/L	78.0	2
Sodium, mmol/L	135.7	0
Creatinine, μmol/L	338.2	2
Glucose, mmol/L	15.79	1

Table 2 The Sequential Organ Failure Assessment score

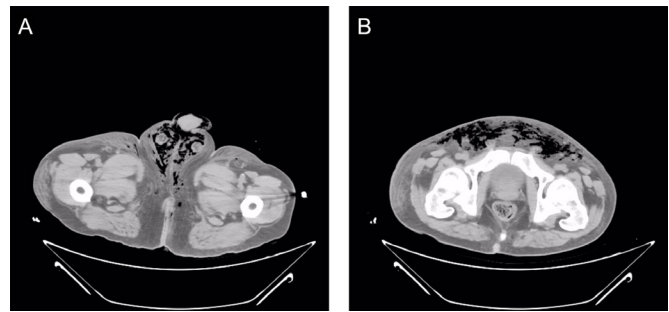
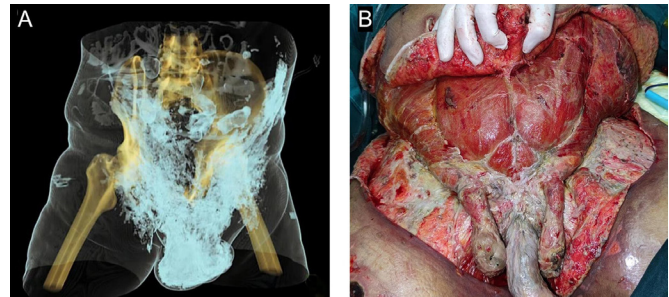
Organ system, measurement	Results	Score
Respiration	112	3
PaO ₂ /FiO ₂ , mm Hg		
Coagulation	22.0	3
Platelets, 10 ³ /mm ³		
Liver	25.1	1
Bilirubin, μmol/L		
Cardiovascular	Norepinephrine	4
Hypotension	2.67 μg/kg/min	
Central nervous system	12	2
Glasgow Coma Score		
Renal	338.2	3
Creatinine, μmol/L		

Severe hyperlactatemia and widespread skin mottling indicate the patient's poor clinical outcome.⁵

NSTI is a surgical emergency requiring aggressive and exhaustive surgical debridement.¹ However, clinical decision-making becomes more challenging when NSTI advances to septic shock and cardiac arrest. Additionally, resuscitation from cardiac arrest precipitates postcardiac arrest syndrome.⁶ In this case, the patient's severely compromised physiological reserves interfered with extensive debridement. Consequently, the damage control surgery (DCS) strategy was implemented, which involves a staged approach to surgery with initial focus on immediate life-threatening conditions.

Different from original DCS that involves three crucial phases: (i) initial abbreviated laparotomy, (ii) intensive ICU resuscitation, and (iii) definitive injury repair during a subsequent laparotomy,⁷ DCS performed in this case entailed multiple tube placements for irrigation, drainage, and decompression of the cavity with septic necrotic tissue and gas, followed by ICU resuscitation and supportive treatment, and thorough debridement. This approach provided temporary infection containment, facilitating repeated debridement. However, incomplete debridement during the initial procedure necessitates delayed thorough debridement and an extended antibiotic regimen, likely facilitating the development of drug-resistant bacterial strains. Moreover, persistent and ongoing systemic inflammation due to residual infection can lead to a protracted state of persistent inflammation, immunosuppression, and catabolic syndrome, considerably lengthening ICU and hospitalization stays.⁸ Hence, this clinical decision needs careful consideration and thorough debridement must be completed without delay once appropriate physiological conditions are achieved.

Patients with NSTI escalating to sepsis or septic shock have an increased mortality rate, even after extensive and thorough debridement during the primary surgery.^{9,10} This successful case suggests that DCS may have potential as an effective treatment for patients with NSTI and physiological exhaustion. Further

**Figure 2** CT scans revealing extensive gas buildup: scrotum and perianal area (panel A), bilateral abdominal wall (panel B).**Figure 3** Range of necrotizing soft tissue infection in three-dimensional CT scan (panel A) and clinical through debridement (panel B).

studies are needed to validate this approach for its potential integration into standard treatment protocols for managing severe NSTI.

CONCLUSION

In patients with NSTI complicated by septic shock, multiple organ failure, and cardiac arrest, DCS may offer a way to salvage those who are initially too critically ill to undergo thorough surgical debridement.

Contributors CZ designed the research. JZ and YZ collected and analyzed the clinical data. JS managed patient treatment and drafted the manuscript. CZ and YC reviewed and revised the manuscript. All authors read and approved the final version.

Funding This research was supported by grants from the Science and Technology Program of Quanzhou (nos: 2021N003S and 2022N005S).

Competing interests None declared.

Patient consent for publication Consent obtained directly from patient(s).

Ethics approval This study was approved by the Medical Ethics Research Committee of Huaqiao University Affiliated Strait Hospital (approval no. 97 (2024)). Participants gave informed consent to participate in the study before taking part.

Provenance and peer review Not commissioned; externally peer reviewed.

Open access This is an open access article distributed in accordance with the Creative Commons Attribution Non Commercial (CC BY-NC 4.0) license, which permits others to distribute, remix, adapt, build upon this work non-commercially, and license their derivative works on different terms, provided the original work is properly cited, appropriate credit is given, any changes made indicated, and the use is non-commercial. See: <http://creativecommons.org/licenses/by-nc/4.0/>.

ORCID iD

Jianshe Shi <http://orcid.org/0000-0001-5486-9244>

REFERENCES

- Hua C, Urbina T, Bosc R, Parks T, Sriskandan S, de Prost N, Chosidow O. Necrotising soft-tissue infections. *Lancet Infect Dis* 2023;23:e81–94.

- 2 Yan Q, Kim J, Hall DE, Shinall MC Jr, Reitz KM, Stitzenberg KB, Kao LS, George EL, Youk A, Wang C-P, *et al.* Association of Frailty and the Expanded Operative Stress Score with Preoperative Acute Serious Conditions, Complications, and Mortality in Males Compared to Females: A Retrospective Observational Study. *Ann Surg* 2023;277:e294–304.
- 3 Daryabor G, Atashzar MR, Kabelitz D, Meri S, Kalantar K. The Effects of Type 2 Diabetes Mellitus on Organ Metabolism and the Immune System. *Front Immunol* 2020;11:1582.
- 4 El-Qushayri AE, Khalaf KM, Dahy A, Mahmoud AR, Benmelouka AY, Ghozy S, Mahmoud MU, Bin-Jumah M, Alkahtani S, Abdel-Daim MM. Fournier's gangrene mortality: A 17-year systematic review and meta-analysis. *Int J Infect Dis* 2020;92:218–25.
- 5 Haas SA, Lange T, Saugel B, Petzoldt M, Fuhrmann V, Metschke M, Kluge S. Severe hyperlactatemia, lactate clearance and mortality in unselected critically ill patients. *Intensive Care Med* 2016;42:202–10.
- 6 Andersen LW, Holmberg MJ, Berg KM, Donnino MW, Granfeldt A. In-Hospital Cardiac Arrest: A Review. *JAMA* 2019;321:1200–10.
- 7 Roberts DJ, Ball CG, Feliciano DV, Moore EE, Ivatury RR, Lucas CE, Fabian TC, Zygun DA, Kirkpatrick AW, Stelfox HT. History of the Innovation of Damage Control for Management of Trauma Patients: 1902-2016. *Ann Surg* 2017;265:1034–44.
- 8 Efron PA, Brakenridge SC, Mohr AM, Barrios EL, Polcz VE, Anton S, Ozrazgat-Baslanti T, Bihorac A, Guirgis F, Loftus TJ, *et al.* The persistent inflammation, immunosuppression, and catabolism syndrome 10 years later. *J Trauma Acute Care Surg* 2023;95:790–9.
- 9 Vilallonga R, Mazarro A, Rodríguez-Luna MR, Caubet E, Fort JM, Armengol M, Guirao X. Massive necrotizing fasciitis: a life threatening entity. *J Surg Case Rep* 2019;2019:rjz269.
- 10 Symeonidou E, Gkoutziotis I, Moulazimi A, Lagopoulos V, Kamaroudis A. Necrotizing Fasciitis of the Breast: A Case Series and Review of the Literature. *Surg Infect (Larchmt)* 2023;24:19–26.