

Large adrenal incidentaloma in conjunction with perforated diverticulitis

Kendell Pon , David Bigam, Nori L Bradley 

General Surgery, University of Alberta, Edmonton, Alberta, Canada

Correspondence to
Dr Kendell Pon; kmpon@ualberta.ca

CASE DESCRIPTION

A middle-aged man with controlled hypertension was admitted to a peripheral hospital with 1 week of abdominal pain and a white cell count of 14. Initial CT showed complicated diverticulitis: locules of free air, inflammation within the central mesentery, and adjacent loops of thickened small bowel and sigmoid colon. There was also an 8 cm solid left adrenal mass. A trial of non-operative management was initiated. Interval CT with rectal contrast on day 5 showed contrast extravasation from a sigmoid diverticulum into a 10 cm abscess (figure 1). Given the unknown diagnosis of the adrenal mass, plans for surgical management required transfer to a tertiary center with resources for appropriate hemodynamic monitoring and perioperative management. Endocrinology initiated a functional workup as well as empiric alpha-blockade.

On arrival, he was clinically stable with minimal pain but persisting obstructive symptoms. A nasogastric tube was in situ and he was on parenteral nutrition. He denied any symptoms attributable to a pheochromocytoma other than occasional 'panic attacks'. Anesthesia and endocrinology reviewed the case in preparation for urgent surgery. Keeping in mind his acute medical stress, the functional workup was completed but unable to be expedited sooner than 1–2 weeks. Alpha-blockade was serially increased and a T2-weighted MRI was completed but indeterminate between an adrenal cortical carcinoma (ACC) versus a pheochromocytoma.

Carcinoembryonic antigen and chest radiographs were normal. Hepatopancreaticobiliary (HPB)/endocrine surgery confirmed the adrenal mass would require open surgery given the current peritonitis and would be available to support operative management of the adrenal mass. On post-transfer day 3, he developed worsening peritonitis with diaphoresis, warranting operative management prior to definitive diagnosis of the large adrenal mass.

WHAT WOULD YOU DO?

A. Sigmoid resection, end colostomy, refer for delayed left adrenalectomy

B. Sigmoid resection, primary anastomosis, loop ileostomy, refer for delayed left adrenalectomy

C. Sigmoid resection, end colostomy, concomitant left adrenalectomy

D. Sigmoid resection, primary anastomosis, loop ileostomy, concomitant left adrenalectomy

WHAT WE DID AND WHY

Answer: C

Informed consent was obtained for a laparotomy, bowel resection, possible stoma, possible resection of the adrenal mass, and possible need for intensive care unit (ICU) management of hemodynamic instability. An arterial line was placed for invasive blood pressure monitoring and induction of general anesthesia was uneventful. Agents to rapidly control hypertensive crisis and arrhythmias were immediately available, with close attention to intraoperative fluid balance. Intraoperative findings included a large pelvic interloop abscess, 30 cm of sigmoid colon requiring resection, and two loops of small bowel densely adhered to the abscess cavity requiring resection due to transmural ischemia (remaining bowel shown in figure 2). The patient was hemodynamically stable throughout the initial bowel resections with minimal manipulation of the adrenal mass.

The sigmoid and small bowel were initially left in discontinuity while the adrenal mass was assessed with HPB/endocrine surgery. As indicated by preoperative imaging, there was no invasion of other structures and the mass was not hypervascular except for a large draining vein (figure 3). A left adrenalectomy was completed in toto, and the patient remained hemodynamically stable. Two handsewn small bowel anastomoses were then created, and an end colostomy fashioned given the significant purulent contamination, the increased risk of postoperative hypotension, upstream anastomoses, and potential need for adjuvant therapy if the diagnosis was ACC. The anastomoses were performed at the end of the procedure in case the patient did develop hemodynamic instability, allowing for the bowel to be reassessed or anastomosed at a later operation if necessary. Drains were left in the pelvis and lesser sac.

While waiting for diagnosis of the adrenal mass would be ideal, this patient required surgery for another urgent condition: complicated diverticulitis failing non-operative management.

Performing the adrenalectomy at this OR saved the patient another major surgery and allowed both procedures to be done using one incision. Definitively proceeding with the adrenalectomy was decided intraoperatively, as the patient tolerated manipulation of the mass without significant hemodynamic changes. If there were any complicating factors making it unsafe to proceed, the adrenalectomy could be abandoned and the patient reassessed for surgical management at a later time.

© Author(s) (or their employer(s)) 2024. Re-use permitted under CC BY-NC. No commercial re-use. See rights and permissions. Published by BMJ.

To cite: Pon K, Bigam D, Bradley NL. *Trauma Surg Acute Care Open* 2024;9:e001380.

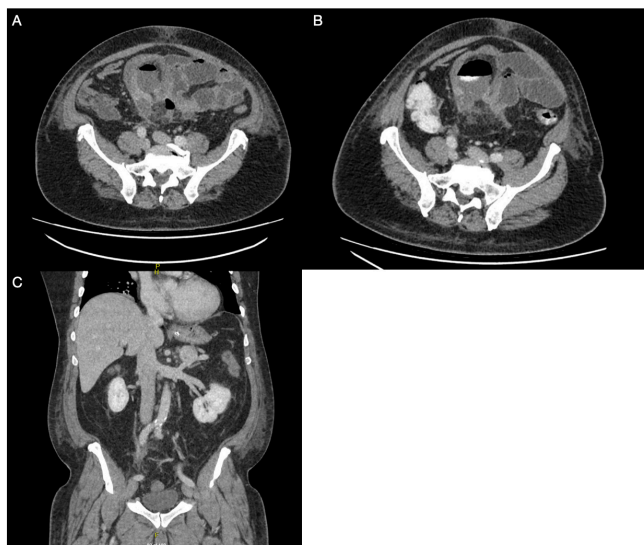


Figure 1 CT scan with (A) intravenous contrast and (B) rectal contrast with extravasation into a 10 cm abscess and (C) demonstrating the prominent draining adrenal vein.

The patient recovered well postoperatively. His blood pressure fell to 110/70 several hours after surgery, however, increased back to a hypertensive range over the next few days. He had an ileus and a low volume pancreatic leak that resolved prior to discharge on postoperative day 9. The 24-hour urine metanephrines came back elevated at 2.5 (reference <1.3 $\mu\text{mol}/\text{day}$) and normetanephrines 44.3 (reference <4.3 $\mu\text{mol}/\text{day}$). Relevant

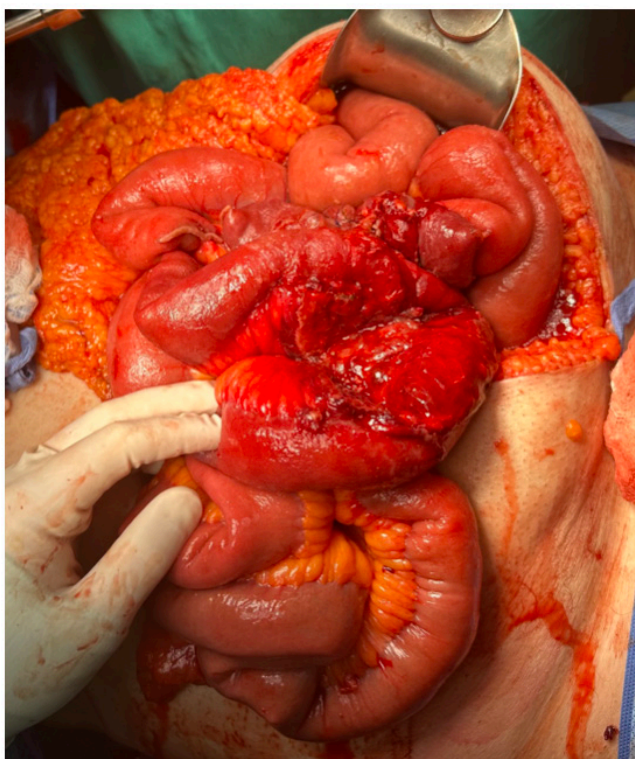

Figure 2 Remaining small bowel that was densely adhered to the abscess cavity.

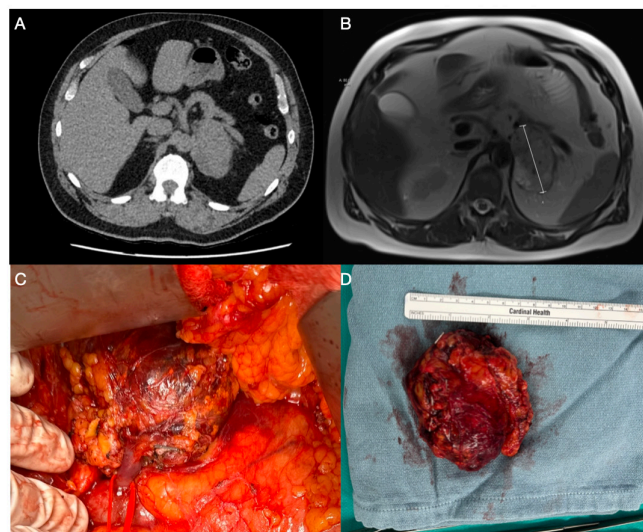


Figure 3 Left adrenal mass (A) on initial unenhanced CT, (B) on T2-weighted MRI, (C) in vivo, and (D) after resection.

final pathological findings revealed perforated diverticular disease (negative for malignancy) and a left pheochromocytoma.

Although perforated diverticulitis is a common presentation on acute care surgery services, pheochromocytomas are rare. They are even more rare to be found incidentally in the setting of another emergency general surgery presentation. Close multi-disciplinary communication is recommended, as well as management in a tertiary center with ICU capability for aggressive hemodynamic intervention and management. Delaying surgery for definitive diagnosis of the adrenal mass would allow medical optimization; however, this is not always possible given the underlying emergency general surgery condition. We describe an approach to managing both conditions simultaneously, with alternatives described depending on the intraoperative findings and patient stability.

Acknowledgements The authors would like to acknowledge their patient who kindly requested his journey be used as a teaching opportunity.

Contributors KP prepared the article draft with NLB and DB providing revisions. NLB was the most responsible physician and the primary operator. DB provided consultant and surgical expertise with regard to the adrenal mass. KP will serve as the guarantor.

Funding The authors have not declared a specific grant for this research from any funding agency in the public, commercial or not-for-profit sectors.

Competing interests None declared.

Patient consent for publication Consent obtained directly from patient(s).

Ethics approval This submission did not require ethics approval as it is not a clinical trial. The patient verbally provided informed consent for his case to be used in this article, and the article is sufficiently anonymized in line with the anonymization policy and checklist.

Provenance and peer review Not commissioned; internally peer reviewed.

Open access This is an open access article distributed in accordance with the Creative Commons Attribution Non Commercial (CC BY-NC 4.0) license, which permits others to distribute, remix, adapt, build upon this work non-commercially, and license their derivative works on different terms, provided the original work is properly cited, appropriate credit is given, any changes made indicated, and the use is non-commercial. See: <http://creativecommons.org/licenses/by-nc/4.0/>.

ORCID iDs

Kendell Pon <http://orcid.org/0000-0003-2040-5251>

Nori L Bradley <http://orcid.org/0000-0001-6966-1964>