


# Secondary manubriosternal joint dislocation displacement in a teenager patient

Thibault Planchamp ,<sup>1</sup> Axel Rouch,<sup>2</sup> Romain Vergé,<sup>2</sup> Laurent Brouchet,<sup>2</sup> Emmanuel Gurrera,<sup>3</sup> Giulia Fusi,<sup>1</sup> Jérôme Sales de Gauzy,<sup>1</sup> Franck Accadbled,<sup>1</sup> Olivier Abbo,<sup>1</sup> Felice Davide Calvaruso,<sup>4</sup> Manon Bolzinger<sup>1</sup>

<sup>1</sup>Department of Paediatric Surgery, Hôpital des Enfants, Toulouse, France

<sup>2</sup>Department of Thoracic surgery, Larrey Hospital, Toulouse, France

<sup>3</sup>Department of Emergencies, Hôpital des Enfants - CHU Toulouse, Hôpital des Enfants, Toulouse, France

<sup>4</sup>Department of Cardiac surgery, Hôpital Purpan, CHU Toulouse, Hôpital Purpan, Toulouse, France

## Correspondence to

Dr Thibault Planchamp; planchamp.t@chu-toulouse.fr

## CASE SUMMARY

A teenage gymnast felt a strong pain with a cracking sound in the sternum while practicing on the parallel bars. The pain occurred without blunt force trauma, requiring them to stop training and to consult the emergency department (ED).

Clinically, they were in pain, hemodynamically stable, without chest wall deformity. A chest X-ray found a non-displaced manubriosternal joint (MSJ) widening (figure 1A). Conservative management with step 1 pain killers and sports contraindication were proposed. For 1 week, the pain was well-managed by pain killers.

On the seventh day, while they were sitting, extreme sternal pain occurred with another cracking sound.

At the ED, we found an exhausted patient in a lot of pain, with difficulty lying down. They were hemodynamically stable with normal oxygen saturation. Severe morphine-seeking pain aggravated by thoracic movement was observed. A chest deformity was also seen. A lateral chest X-ray found a posterior dislocation of the sternal body over the manubrium (figure 1B). A chest computed tomography scan with intravenous contrast revealed a fracture hematoma, without other chest lesion (figure 1C,D). ECG and troponin I and T were undisturbed.

Finally, because the patient was stable and their pain was well controlled, they were released home with step 3 painkillers, sports contraindication for 3 months, and a follow-up consultation 3 weeks later with a chest X-ray.

During the follow-up consultation, persistent and severe pain despite morphine, difficulty breathing, and a significant impact on schooling were reported. No bone callus or new displacement were found on the chest X-ray.

## WHAT WOULD YOU DO NEXT?

- Continue conservative management with monitoring and painkillers at home, along with follow-up consultations.
- Perform conservative treatment with manipulative hyperflexion reduction.
- Perform conservative treatment with rehabilitation by distraction osteogenesis.
- Perform surgical stabilization of the MSJ dislocation with plates and screws.
- Perform surgical stabilization of the MSJ dislocation with wires.

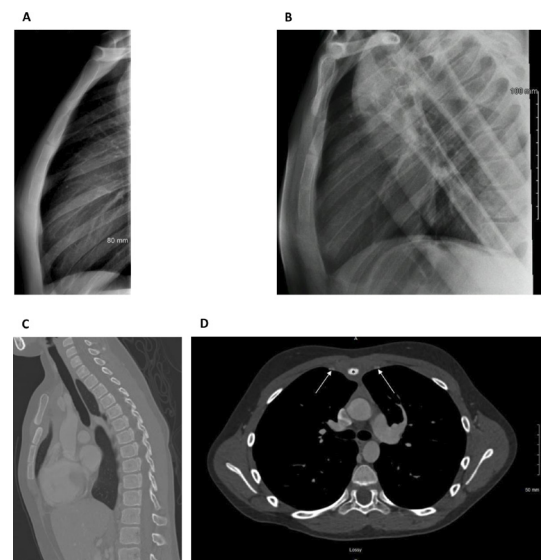
## WHAT WE DID AND WHY

D. Perform surgical stabilization of the MSJ dislocation with plates and screws.

After a literature review and because of the significant impact on the patient's everyday life with severe pain despite morphine, as well as difficulty breathing, pediatric surgeons decided to offer surgical stabilization of the MSJ dislocation.

The operation took place 20 days after secondary displacement and was performed by pediatric orthopedic and cardiac surgeons, based on a previous MSJ dislocation case report published by Nijs and Broos in 2005.<sup>1</sup>

After general endotracheal anesthesia, with the patient in the supine position, a 7 cm midsternal incision was made over the MSJ dislocation. After debridement of the MSJ and liberation of the anterior periosteum, an unconsolidated MSJ dislocation was found (figure 2A). After resection of the fibrosis, the sternum was reduced to the

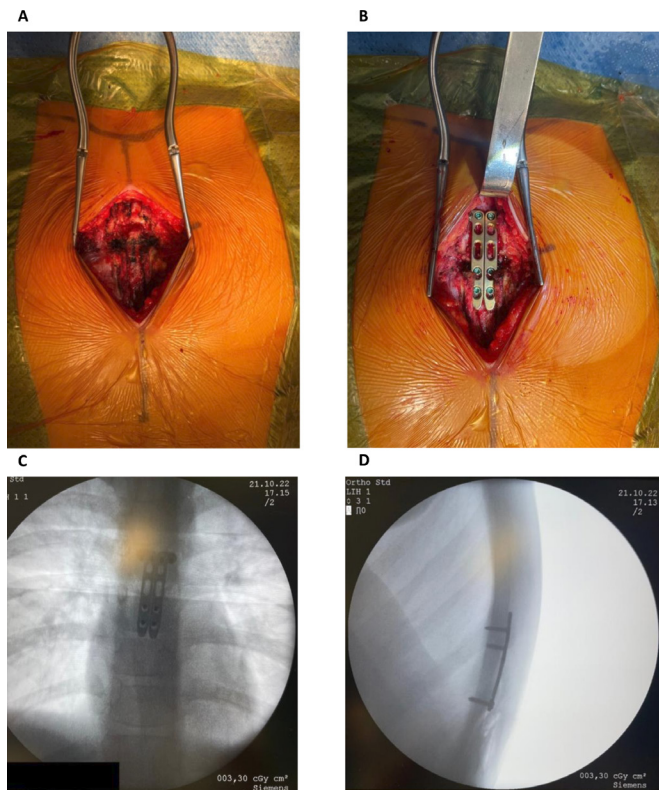


**Figure 1** (A) First sagittal chest X-ray realized the day of initial trauma: a manubriosternal joint dislocation without displacement is found. (B) Sagittal chest X-ray the day of secondary displacement revealing an 8 mm posterior dislocation of the sternal body over the manubrium. (C, D) Preoperative sagittal and axial computed tomography scan: a dislocation hematoma without mediastinal injuries is noted. Sternal body (marked by an asterisk) is surrounded by hematoma. Internal thoracic arteries (marked by arrows) are free of lesions.

© Author(s) (or their employer(s)) 2024. Re-use permitted under CC BY-NC. No commercial re-use. See rights and permissions. Published by BMJ.

## To cite:

Planchamp T, Rouch A, Vergé R, et al. *Trauma Surg Acute Care Open* 2024;**9**:e001259.



**Figure 2** (A) Operating field view after a 7 cm midsternal incision and debridement of the manubriosternal joint. (B) Osteosynthesis with two L-shaped plates, two 2.4 mm non-locking standard screws at the top of the plates, and four 2.4 mm angular stable locking screws at the bottom of the plates. (C, D) Intraoperative chest X-ray control after osteosynthesis showing a perfect correction of the displacement.

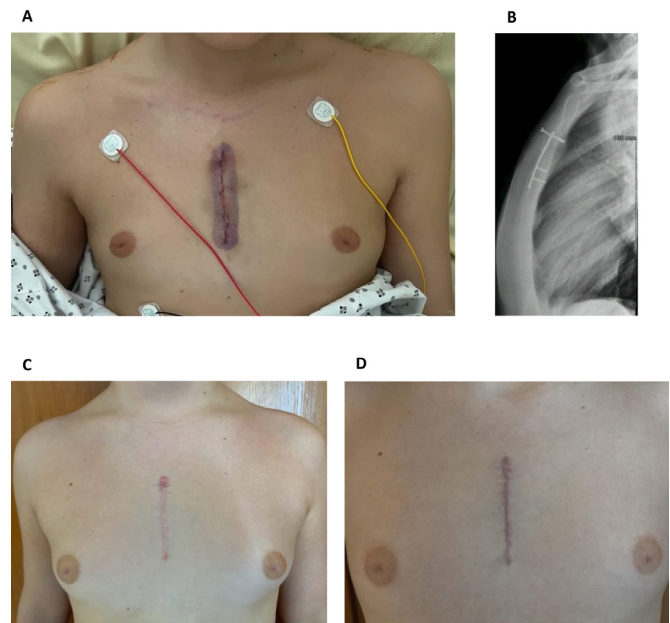
manubrium using a reduction clamp. Osteosynthesis between the manubrium and the sternal body was carried out using two L-shaped plates (Synthes, left and right LCP dorsal distal radius L-plate 2.4, TiCP-442.501 and TiCP-442.503), two 2.4 mm non-locking standard screws (Synthes, Cortex StarDrive 2.4 mm, self-tapping, TAN-401.762) at the top of the plates, and four 2.4 mm angular stable locking screws (Synthes, Locking Screw StarDrive 2.4 mm, self-tapping, TAN-412.810) at the bottom of the plates. Two non-locking standard screws were used because no other angular stable locking screws were available (figure 2B). Good stabilization was obtained at the end (figure 2C,D). The anterior periosteum and the wound were closed in layers without suction drainage tubes (figure 3A). The intraoperative chest X-ray showed perfect correction of the displacement.

Postoperative recovery was uneventful, and they were discharged on the fifth postoperative day with a step 1 pain killer, sports contraindication for 6 months, and a first follow-up visit with a chest X-ray 6 weeks post-operation.

The first follow-up visit showed a satisfactory outcome with well-aligned and stable sternal healing on the chest X-ray and CT scan.

Neuropathic pain was the main complication for the first 2 months, which was well-managed by lidocaine patches.

Sternal pain returned 7 months post-operation. A chest X-ray found migration of the left non-locking standard screw, motivating its quick removal using the original scar through a short proximal incision (figure 3B).



**Figure 3** (A) Surgical scar at postoperative day 3. (B) Migration of the left non-locking standard screw causing pain at postoperative month 7. (C) Surgical scar 9 months after initial operation. Redo operation with screw removal can be seen at the top of the scar. (D) Surgical scar 6 months after plates and screws removal.

Nine months post-operation, the young patient was pain-free, allowing moderate physical activity resumption (figure 3C). The patient was seen several times for follow-up visits with a chest X-ray until we obtained a satisfactory consolidation of the sternum.

Removal of osteosynthesis material was performed 15 months after the initial operation, and the patient continues to do well, allowing normal physical activity resumption. Good cosmetic results were obtained 6 months after the last operation (figure 3D).

This case shows us a rare evolution of an initially non-displaced MSJ dislocation with secondary non-traumatic displacement. Given our literature review, there is currently no consensual management for pediatric sternal fractures and dislocations.<sup>2</sup>

Children presenting at the ED with non-surgically managed MSJ displacement must be seen quickly in consultation by a pediatric surgeon to look for secondary displacement with a chest X-ray (1 week for example). Later consultation checks the reduction quality by bone remodeling with a new chest X-ray.

If conservative treatment is chosen, clear advice should be given. In our center, we advise avoiding carrying heavy loads (more than 5 kg) for 3 months. Sports should be stopped for 3 or 6 months for contact sports.

Because of noble organ presence behind the MSJ and the risk of immediate life-threatening injuries in case of damage, as well as the risk of mistreatment complications (chronic pain syndrome, recurrence, subluxation, pseudoarthrosis, structural deformity, periarticular calcification, and ankylosis),<sup>3,4</sup> we think that secondary MSJ dislocation displacement is a good indication for surgical treatment. Sternal plating seems to be the treatment of choice in these cases, with good follow-up results.<sup>5-8</sup>

Finally, a multidisciplinary approach including pediatric, orthopedic, and visceral surgeons, acute pain services and

physiotherapists will be necessary to achieve optimal functional outcomes and avoid chest wall and pulmonary complications.<sup>4</sup>

**Contributors** All authors contributed significantly to the article.

**Funding** The authors have not declared a specific grant for this research from any funding agency in the public, commercial or not-for-profit sectors.

**Competing interests** None declared.

**Patient consent for publication** Consent obtained directly from patient(s).

**Ethics approval** This study is a case report. This is not a retrospective epidemiological study in which data from several patients are collected in files. It is simply the sharing of a clinical case we were confronted with. On the advice of our institutional board, signing the BMJ patient consent was sufficient. Participants gave informed consent to participate in the study before taking part.

**Provenance and peer review** Not commissioned; internally peer reviewed.

**Open access** This is an open access article distributed in accordance with the Creative Commons Attribution Non Commercial (CC BY-NC 4.0) license, which permits others to distribute, remix, adapt, build upon this work non-commercially, and license their derivative works on different terms, provided the original work is properly cited, appropriate credit is given, any changes made indicated, and the use is non-commercial. See: <http://creativecommons.org/licenses/by-nc/4.0/>.

#### ORCID iD

Thibault Planchamp <http://orcid.org/0000-0002-8693-2866>

#### REFERENCES

- 1 Nijs S, Broos PLO. Sterno-manubrial dislocation in a 9-year-old gymnast. *Acta Chir Belg* 2005;105:422–4.
- 2 Harston A, Roberts C. Fixation of sternal fractures: a systematic review. *J Trauma* 2011;71:1875–9.
- 3 Sarkeshik AA, Jamal A, Perry PA. Manubriosternal joint dislocation due to blunt force trauma. *Trauma Case Rep* 2019;21:100187.
- 4 De la Cruz Garcia I, Wullschleger M. Extensive traumatic anterior chest wall injury including type I manubriosternal dislocation. *Trauma Case Rep* 2022;40:100669.
- 5 Zhao Y, Yang Y, Gao Z, Wu W, He W, Zhao T. Treatment of traumatic sternal fractures with titanium plate internal fixation: a retrospective study. *J Cardiothorac Surg* 2017;12:22.
- 6 Woo CC. Traumatic manubriosternal joint subluxations in two basketball players. *J Manipulative Physiol Ther* 1988;11:433–7.
- 7 Krinner S, Grupp S, Oppel P, Langenbach A, Hennig FF, Schulz-Drost S. Do low profile implants provide reliable stability in fixing the sternal fractures as a 'fourth vertebral column'? *J Thorac Dis* 2017;9:1054–64.
- 8 Schulz-Drost S, Oppel P, Grupp S, Schmitt S, Carbon RT, Mauerer A, Hennig FF, Buder T. Surgical fixation of sternal fractures: preoperative planning and a safe surgical technique using locked titanium plates and depth limited drilling. *J Vis Exp* 2015;J Vis Exp:e52124.