

Failure after operative repair is higher for ballistic femoral neck fractures than for closed, blunt-injury fractures: a multicenter retrospective cohort study

Henry Tout Shu ,¹ Diane Ghanem,¹ Davis L. Rogers,¹ Oscar Covarrubias,¹ Paul IZard,² Jacques Hacquebord,² Philip Lim,³ Ranjan Gupta,³ Greg M. Osgood,¹ Babar Shafiq¹

► Additional supplemental material is published online only. To view, please visit the journal online (<https://doi.org/10.1136/tsaco-2023-001241>).

¹Orthopedic Surgery, The Johns Hopkins Hospital, Baltimore, Maryland, USA

²Orthopaedic Surgery, New York University Grossman School of Medicine, New York, New York, USA

³Orthopaedic Surgery, University of California Irvine School of Medicine, Irvine, California, USA

Correspondence to

Henry Tout Shu; henryshu16@gmail.com

ABSTRACT

Introduction The purpose of this study was to describe the outcomes after operative repair of ballistic femoral neck fractures. To better highlight the devastating nature of these injuries, we compared a cohort of ballistic femoral neck fractures to a cohort of young, closed, blunt-injury femoral neck fractures treated with open reduction and internal fixation (ORIF).

Methods Retrospective chart review identified all patients presenting with ballistic femoral neck fractures treated at three academic trauma centers between January 2016 and December 2021, as well as patients aged ≤ 50 with closed, blunt-injury femoral neck fractures who received ORIF. The primary outcome was failure of ORIF, which includes the diagnosis of non-union, avascular necrosis, conversion to total hip arthroplasty, and conversion to Girdlestone procedure. Additional outcomes included deep infection, postoperative osteoarthritis, and ambulatory status at last follow-up.

Results Fourteen ballistic femoral neck fractures and 29 closed blunt injury fractures were identified. Of the ballistic fractures, 7 (50%) patients had a minimum of 1-year follow-up or met the failure criteria. Of the closed fractures, 16 (55%) patients had a minimum of 1-year follow-up or met the failure criteria. Median follow-up was 21 months. 58% of patients with ballistic fractures were active tobacco users. Five of 7 (71%) ballistic fractures failed, all of which involved non-union, whereas 8 of 16 (50%) closed fractures failed ($p=0.340$). No outcomes were significantly different between cohorts.

Conclusion Our results demonstrate that ballistic femoral neck fractures are associated with high rates of non-union. Large-scale multicenter studies are necessary to better determine optimal treatment techniques for these fractures.

Level of evidence Level III. Retrospective cohort study.

INTRODUCTION

Firearm injuries remain a major US public health issue, with an annual average of 85,694 emergency department visits per year between 2009 and 2017 for non-fatal firearm injuries.¹ Ballistic femoral neck fractures are exceedingly rare and are typically due to gunshot injury.²⁻¹⁰ Previous case series regarding ballistic fractures of the proximal femur have included peritrochanteric, femoral head, and femoral neck fractures.^{4,7,8} In 2020, Maqungo *et al* reported 15 ballistic femoral neck fractures in their

WHAT IS ALREADY KNOWN ON THIS TOPIC

⇒ Ballistic femoral neck fractures are rare injuries with few studies examining outcomes after operative repair of this injury.

WHAT DOES THIS STUDY ADDS

⇒ This study demonstrates that operative repair of ballistic femoral neck fractures has a very high rate of failure and was associated with a non-union rate of 71%.

HOW THIS STUDY MIGHT AFFECT RESEARCH, PRACTICE OR POLICY

⇒ Our results suggest that future studies should explore primary total hip arthroplasty versus operative repair of these fractures.

cohort of 32 patients with ballistic fractures of the hip.⁸ Of those patients, 4 (26%) of 15 femoral neck fractures failed, most commonly due to dynamic hip screw cut-out.⁸ Notably, other studies have also reported poor outcomes after these fractures, with high rates of failure and/or conversion to total hip arthroplasty (THA).⁷

Furthermore, these injuries tend to occur in younger patients, which makes the decision to perform primary arthroplasty challenging.^{2,4} Because arthroplasty in young patients is expected to result in future revision procedures secondary to normal implant wear, management of femoral neck fractures in young patients classically involves preservation of the native femoral head with open reduction and internal fixation (ORIF).^{11,12} However, in some cases, there may be such extensive fracture comminution that ORIF may be non-feasible in ballistic fractures.¹⁰

To date, there have been no studies exclusively examining ballistic femoral neck fractures. Additionally, there have been no studies that have compared the outcomes after these injuries to that of closed, blunt-injury femoral neck fractures in young patients. Therefore, the purpose of this study was to describe the outcomes after operative repair of ballistic femoral neck fractures. To better highlight the devastating nature of these injuries, we compared a cohort of ballistic femoral neck fractures to a cohort of closed, blunt-injury femoral neck fractures treated with ORIF.

© Author(s) (or their employer(s)) 2024. Re-use permitted under CC BY-NC. No commercial re-use. See rights and permissions. Published by BMJ.

To cite: Shu HT, Ghanem D, Rogers DL, *et al*. *Trauma Surg Acute Care Open* 2024;**9**:e001241.

Table 1 Overall patient factors

	Ballistic femoral neck fractures	Closed Blunt-Injury femoral neck fractures	P value
	N=14	N=29	
Age (years)	26 (23 to 29)	36 (25 to 42)	0.078
Gender (female)	2 (14%)	6 (21%)	0.613
BMI	22.4 (19.4 to 25.1)	23.7 (20.8 to 26.5)	0.476
Active tobacco use	7 (58%)	7 (24%)	0.090
Diabetes	0 (0%)	2 (7%)	0.314
Length of hospital stay (days)	7 (4 to 12)	6 (4 to 10)	0.907
Follow-up (months)	6 (2 to 21)	12 (6 to 21)	0.364
Minimum 1-year follow-up	6 (43%)	15 (52%)	0.586
Minimum 1-year follow-up or met failure criteria*	7 (50%)	16 (55%)	0.750

Values are represented as median (IQR) or as the number of patients (percentage of the group) where appropriate. P values are from the Wilcoxon rank-sum test or χ^2 test.

*Failure criteria include non-union, avascular necrosis, conversion to total hip arthroplasty, or conversion to Girdlestone procedure.

BMI, body mass index.

METHODS

Institutional Review Board approval was obtained at three urban Level 1 trauma centers, with three institutions located on the East Coast and one institution located on the West Coast of the USA. Retrospective chart review was then performed to identify all patients who had undergone operative management of femoral neck fractures between January 2016 and December 2021. These patients were identified with the CPT codes 27235 (percutaneous fixation femoral neck fracture) and 27236 (open treatment of femoral neck fracture, with internal fixation or hemiarthroplasty). Electronic medical records were then manually reviewed to identify ballistic fractures. All patients presenting with ballistic fractures were included. A comparison cohort, which included consecutive patients ≤ 50 years of age with blunt-injury femoral neck fractures who were treated with ORIF over the same time period was identified. The closed, blunt-injury cohort only had the CPT code of 27236. The operative reports of these patients were manually reviewed to verify that all patients had received an open reduction. A total of 14 ballistic femoral neck fractures and 29 young, closed, blunt-injury femoral neck fractures that received ORIF were identified over the specified time period (table 1). The rationale for comparing ballistic fractures to a cohort of young (≤ 50 years of age), closed, blunt-injury femoral neck fractures that received ORIF was that these fractures classically have high rates of major complications, such as non-union, osteonecrosis of the femoral head, and malunion.^{13 14} Recently, the Young Femoral Neck Fracture Working Group has demonstrated that young patients (< 50 years of age) with femoral neck fractures had an overall major complication rate of 45%, with 32% of all patients undergoing subsequent major reconstructive operation.¹³ Thus, we hypothesized that these patients represent a more optimal comparison group with whom to compare outcomes. This study fulfills the Strengthening the Reporting of Observational Studies in Epidemiology (STROBE) guidelines for retrospective cohort studies.

Patient factors, fracture characteristics, and surgical factors

Patient factors included age, gender, body mass index (BMI), active tobacco use, type 2 diabetes mellitus diagnosis, length of hospital stay, and length of final orthopedic follow-up. The length of orthopedic follow-up was defined as the time between the date of operation and the final follow-up visit that included radiographs and/or CT imaging of the fracture. Fracture characteristics included fracture displacement and the *Arbeitsgemeinschaft für Osteosynthesefragen* Foundation/Orthopaedic Trauma Association (AO/OTA) classification.¹⁵ Surgical factors included time from injury to operation, type of implants used, surgical approach for reduction, and fracture reduction quality. Type of implants included cannulated screws, dynamic hip screw, blade plate, and modern fixed angle constructs, which included either the Femoral Neck System (DePuy Synthes, West Chester, PA) or the Conquest FN (Smith & Nephew, Warford, England, UK). The fracture reduction quality was graded as excellent reduction (< 2 mm of displacement and < 5 degrees of angulation in any plane), good reduction (2 to 5 mm displaced and/or 5 to 10 degrees of angulation), fair reduction (> 5 to 10 mm displaced and/or > 10 to 20 degrees of angulation), and poor reduction (> 10 mm displaced and/or > 20 degrees of angulation) per Haidukewych *et al.*¹¹ Reduction quality was graded by the treating surgeons at each institution.

Outcomes

The primary outcome was failure of ORIF, which includes the diagnosis of non-union, avascular necrosis, conversion to THA, and conversion to Girdlestone procedure. Additional outcomes included deep infection, postoperative osteoarthritis, and ambulatory status at last follow-up. Non-union was defined as failure of fixation, which includes implant breakage and/or loss of reduction, or persistence of a visible fracture line at a minimum of 6 months after ORIF.¹¹ Postoperative osteoarthritis was defined by the presence of joint space narrowing, osteophytes, subchondral sclerosis, and/or subchondral cysts on postoperative hip radiographs. Deep infection was defined as any infection requiring subsequent operation, which includes irrigation and debridement with or without removal of hardware and/or Girdlestone procedure.

Statistical analysis

Patients were included for outcomes analysis if they met failure criteria or if they had a minimum of 1-year follow-up. Of the ballistic fractures, 7 (50%) of 14 patients had a minimum of 1-year follow-up or met the failure criteria, and thus were included for outcomes analysis (table 1). Of the closed, blunt-injury femoral neck fractures, 16 (55%) of 29 patients had a minimum of 1-year follow-up or met the failure criteria, and thus were included for outcomes analysis (table 1). The Wilcoxon rank-sum test was used to compare continuous variables between ballistic fractures and closed, blunt-injury fractures as no continuous variables were found to be normally distributed by Shapiro-Wilk testing. Continuous variables are reported as median (IQR) because no variables were found to be normally distributed. χ^2 testing was used to compare categorical variables between groups. An α value of 0.05 was used. Patients with missing data were excluded from analysis. Any missing data is reported in the tables.

RESULTS

Patient factors, fracture characteristics and surgical factors

A total of 14 ballistic femoral neck fractures and 29 closed, blunt-injury femoral neck fractures that received ORIF were

Table 2 Overall fracture characteristics and surgical factors

	Ballistic femoral neck fractures	Closed blunt-injury femoral neck fractures	P Value
	N=14	N=29	
Time from injury to operation (days)	1 (0 to 1)	1 (0 to 1)	0.363
Displaced fracture	11 (79%)	29 (100%)	0.010
AO classification			
Subcapital* (31B1)	5 (36%)	5 (17%)	
Transcervical* (31B2)	5 (36%)	17 (59%)	
Basical* (31B3)	1 (7%)	5 (17%)	0.009
Unreported	3 (21%)	2 (7%)	
Implants			
Cannulated screw	4 (29%)	8 (28%)	
Dynamic hip screw	5 (36%)	14 (48%)	
Modern fixed angle construct†	1 (7%)	6 (21%)	
Blade plate	3 (21%)	1 (3%)	0.190
Unreported	1 (7%)	0 (0%)	
Surgical approach for reduction			
Direct anterior (Smith-Peterson)	8 (57%)	23 (79%)	
Anterolateral (Watson-Jones)	2 (14%)	6 (21%)	
Closed reduction	4 (29%)	0 (0%)	0.010
Fracture reduction quality‡			
1—Excellent	7 (50%)	22 (76%)	
2—Good	2 (14%)	3 (10%)	
3—Fair	1 (7%)	2 (7%)	
4—Poor	0 (0%)	0 (%)	0.737
Unreported	4 (29%)	2 (%)	

Values are represented as median (IQR) or as the number of patients (percentage of the group). P values are from the Wilcoxon rank-sum test or χ^2 test.
 *Per the AO/OTA (2018) fracture compendium.¹⁴
 †Either the Femoral Neck System (DePuy Synthes, West Chester, PA) or Conquest FN (Smith & Nephew, Warford, England, UK).
 ‡Fracture reduction was graded as excellent (<2 mm of displacement and <5 degrees of angulation in any plane), good (2 to 5 mm displaced and/or 5 to 10 degrees of angulation), fair (>5 to 10 mm displaced and/or >10 to 20 degrees of angulation), and poor (>10 mm displaced and/or >20 degrees of angulation) per Haidukewych *et al.*¹¹

identified (table 1). Patients with ballistic femoral neck fractures had a median (IQR) age of 26 years (23 to 29 years) and BMI of 22.4 (19.4 to 25.1). Patients with closed, blunt-injury fractures had a median (IQR) age of 36 years (25 to 42 years) and BMI of

23.7 (20.8 to 26.5). Median follow-up was 21 months (13 to 32 months) for ballistic fractures and 21 months (13 to 31 months) for closed, blunt-injury fractures included in outcomes analysis. No patient factors were significantly different between the two groups (table 1). When examining only patients with a minimum of 1 year follow-up or who have met the failure criteria, no patient factors, fracture characteristics, or surgical factors were significantly different between patients with ballistic fractures and patients with closed, blunt-injury fractures (online supplemental tables 1 and 2).

Overall, patients with ballistic fractures had a greater percentage of closed reductions compared with the closed, blunt-injury group (29% vs 0%, $p=0.010$) as the ballistic femoral neck fracture group had fewer displaced fractures (79% vs 100% displaced, $p=0.010$) (table 2). The closed, blunt-injury group had a greater proportion of transcervical fractures (59% vs 36%, $p=0.009$). Time to operation, type of implants used, and fracture reduction quality were not significantly different between the two groups. Notably, no ballistic fractures were treated with primary THA. Thirteen (93%) of 14 patients received ORIF of their ballistic fracture. Notably, one patient with a ballistic femoral neck fracture had such extensive fracture comminution that a reduction could not be performed (figure 1A). Thus, a salvage procedure with a vascularized fibular strut autograft to reconstruct the femoral neck was performed with a blade plate for neutralization (figure 1B). Unfortunately, the patient was lost to follow-up shortly after his hospitalization but returned to clinic 3 years postoperatively. At that point, his radiographs demonstrated collapse of the fixation construct with breakage of the blade plate (figure 1C). The patient was offered THA but deferred it. He did not have any interval follow-up and did not elect any revision operation.

Outcomes

When examining only patients with a minimum of 1-year follow-up or who have met the failure criteria, none of the outcomes were significantly different between the groups (table 3). Notably, 71% of ballistic femoral neck fractures failed as compared with 50% of closed, blunt-injury fractures ($p=0.340$) (table 3). All five of the ballistic fractures that failed developed non-union, with one patient requiring conversion to THA as they had also developed avascular necrosis (table 3). Only one patient with a displaced ballistic femoral neck fracture did not experience failure. The radiographs of that patient at 1-year follow-up are demonstrated in figure 2.

DISCUSSION

The results of our study demonstrate that ballistic femoral neck fractures had very high complication rates and poor outcomes.

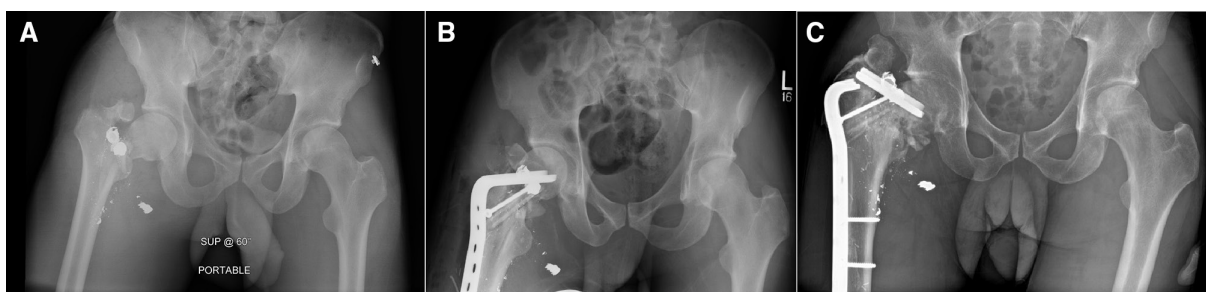

Figure 1 (A) Preoperative anterior-posterior (AP) pelvic radiographs demonstrating a right ballistic femoral neck fracture with obliteration of the entire neck. (B) Immediate postoperative AP pelvis radiograph after treatment with a vascularized fibular graft femoral neck reconstruction stabilized by a blade plate. (C) Final 3-year follow-up radiographs demonstrating non-union with hardware failure. The patient did not have any interval follow-up and did not elect revision operation.

Table 3 Outcomes of patients with a minimum of 1-year follow-up or who have met the failure criteria*

	Ballistic femoral neck fractures N=7	Closed blunt-injury femoral neck fractures N=16	P value
Met failure criteria*	5 (71%)	8 (50%)	0.340
Follow-up (months)	21 (13 to 32)	21 (13 to 31)	0.893
Non-union	5 (71%)	6 (38%)	0.134
Avascular necrosis	1 (14%)	1 (6%)	0.529
Conversion to total hip arthroplasty	1 (14%)	2 (13%)	0.907
Conversion to Girdlestone procedure	0 (0%)	1 (6%)	0.499
Deep postoperative infection	1 (14%)	2 (13%)	0.907
Postoperative hip osteoarthritis	0 (0%)	0 (0%)	1.000
Ambulatory status at final follow-up			
Unassisted	5 (71%)	13 (81%)	
Required assisted gait device	1 (14%)	2 (13%)	
Non-ambulatory	1 (14%)	1 (6%)	0.805

Values are represented as median (IQR) or as the number of patients (percentage of the group). P values are from the Wilcoxon rank-sum test or χ^2 test.
*Failure criteria include non-union, avascular necrosis, conversion to total hip arthroplasty, or conversion to Girdlestone procedure.

With a minimum follow-up of 1 year, 5 (71%) out of 7 patients with ballistic femoral neck fractures failed, with all 5 of those failures being non-union. Of those five failures, one patient also had avascular necrosis and was converted to a THA. Although, the outcomes were not significantly different between cohorts, likely due to small sample size, this study provides insight into the high complication rates of young adults ballistic femoral neck fractures relative to those with closed blunt injuries. Notably, the 50% failure rate of our blunt-injury cohort is similar to the 45% failure rate of young femoral neck fractures receiving ORIF as reported by Collinge *et al.*¹³ Similar to this study, Collinge *et al.*'s definition of failure included non-union, osteonecrosis,

and any secondary major reconstructive operation.¹³ However, they also included malunion, which was defined as vertical or femoral neck shortening of ≥ 10 mm, which was not assessed in this present study.¹³

The non-union rate of our ballistic femoral neck fractures is greater than the non-union rates reported in previous studies examining these fractures. Zhang *et al* reported an overall non-union rate of 9% in 69 patients with ballistic hip fractures.⁷ However, their cohort also included peritrochanteric fractures, and thus the failure rate of their ballistic femoral neck fractures independent of other hip fractures is unclear. Interestingly, they reported that 65% of their ballistic fracture patients were active tobacco users, which is similar to our cohort. These findings suggest that the active tobacco use in this patient population may partially contribute to the high rate of non-union, as tobacco use has been identified as a risk factor for non-union in multiple studies.^{16,17} Similarly, in an abstract presented at the Orthopaedic Trauma Association 2020 meeting, Jo *et al* reported a non-union rate of 15% in 20 patients with ballistic femoral neck fractures, which is far lower than the non-union rate in our cohort of 83%.¹⁸ The discrepancy between Jo *et al.*'s non-union rate and the non-union rate in this study may be due to the fact that we had only included patients in our outcomes analysis if they had a minimum 1-year follow-up or if they failed earlier than 1 year. Nevertheless, ballistic femoral neck fractures generally seem to have far greater rates of non-union than that of young blunt-injury femoral neck fractures, which have a non-union rate of 8% to 9%.^{11,19} Moreover, our displaced fracture failure rate of 71%, which were primarily due to non-union, is similar to the failure rate of Maqungo *et al.*'s cohort.⁸ When examining only their patients with greater than 6 months of follow-up, 100% (4 of 4) of their ballistic femoral neck fractures required revision operation.⁸

We hypothesize that the high rate of non-union in ballistic fractures may be due to severe fracture comminution, which can preclude successful ORIF, and the high rates of active tobacco use in this patient population. Recently, Collinge *et al* demonstrated that young patients with femoral neck fractures undergoing ORIF have a technical error rate of 50%, which was associated with an increased risk of treatment failure, especially in displaced fractures.¹⁴ As ballistic femoral neck fractures can have far more

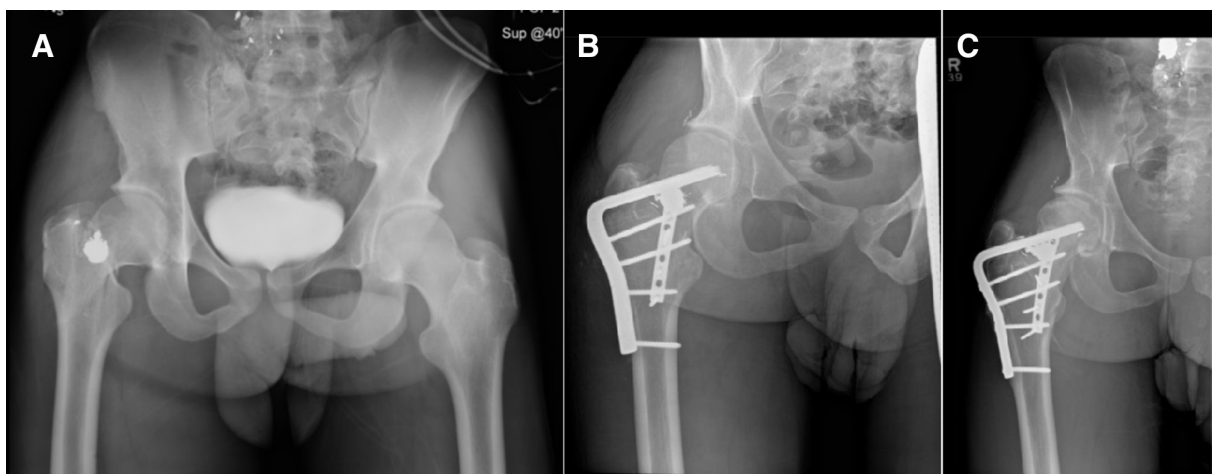


Figure 2 (A) Preoperative anterior-posterior (AP) pelvic radiographs demonstrating a displaced right ballistic femoral neck fracture. (B) One-month postoperative AP hip radiograph demonstrating fixation with a blade plate. Additionally, a 2.7 mm buttress plate was applied anterior-inferiorly on the femoral neck to aid in achieving reduction of the femoral neck. (C) One-year follow-up AP hip radiograph demonstrating healing of the femoral neck with no breakage of implants.

comminution than blunt-injury fractures, one would expect that there may be a greater rate of technical errors in these patients secondary to an increased difficulty of achieving an appropriate reduction. Interestingly, in our cohort, the fracture reduction quality for patients with displaced ballistic femoral neck fractures with a minimum 1-year follow-up were graded as either excellent (50%) or good (33%) (online supplemental table 2), suggesting that technical errors regarding reduction may not have played a major role in the poor outcomes in our patients.

Given the high rates of failure in these injuries, there may be a role for evaluation of the femoral neck blood supply after these fractures to determine the feasibility of ORIF.^{20 21} Furthermore, the high rates of failure in these young patients suggest that primary THA may be a potential treatment option in these patients. Recently, Bell *et al* reported performing primary THA for a ballistic femoral neck fracture with severe comminution of the neck.¹⁰ Interestingly, the injury radiographs in their patient are similar to the injury radiographs of our patient shown in figure 1, which demonstrated severe comminution of the femoral neck that was irreducible. They demonstrate that at 2-year follow-up, the patient had excellent outcomes with full return to activity.¹⁰ Nevertheless, we were hesitant to perform primary THA in these ballistic fractures due to their young age and the need for future revision, as studies have demonstrated 10-year THA revision rates to be about 10% in young patients.^{22 23} Additionally, younger patients will likely need to undergo multiple revision procedures, with each revision having shorter survival periods.²⁴

Limitations

A major limitation of this study is sample size, as there were only 14 ballistic injuries over a 5-year period between three institutions. This small sample size also precluded us from performing multivariable logistic regression to adjust for potential confounders regarding failure and non-union. For instance, although we had observed that a large proportion of patients with ballistic fractures had active tobacco use (58%), we were unable to draw conclusions regarding its effect on the risk of failure or non-union. Additionally, the retrospective nature of this study, which included the grading of fracture reduction by the treating surgeon, precludes us from excluding assessment bias, as surgeons may tend to underestimate the number and severity of their own complications in chart documentation. Furthermore, the limited 1-year follow-up of about 50% in both cohorts limits our ability to form conclusions regarding avascular necrosis, post-traumatic hip osteoarthritis, and conversion to THA. Nevertheless, the high rate of non-union and failure in our cohort, despite the relatively limited follow-up, suggests that ballistic femoral neck fractures are devastating injuries with poor outcomes after ORIF.

CONCLUSION

Although ORIF is often considered the optimal treatment in young patients, our results demonstrate that ballistic femoral neck fractures have high rates of non-union. These results help surgeons in counseling patients with these fractures about the high likelihood of requiring revision operation. Large-scale multicenter studies are necessary to better determine optimal treatment techniques for these fractures, which may involve primary THA.

Contributors HS conceived and designed the study, performed data collection and analysis, and was involved in manuscript drafting and editing. DG, DR, OC, PI, JH, PL, RG, GO, and BS were involved in reviewing data analysis, manuscript drafting,

and editing. PI was also involved in data collection. BS was also responsible for overseeing data sharing between all of the organizations. BS is the guarantor of this study.

Funding The authors have not declared a specific grant for this research from any funding agency in the public, commercial or not-for-profit sectors.

Competing interests None declared.

Patient consent for publication Not applicable.

Ethics approval This study was approved by the Johns Hopkins Medicine Institutional Review Board (IRB00306722 – Main coordinating center), University of California Irvine Health Institutional Review Board, and the New York University Langone Health Institutional Review Board. All Institutional Review Boards determined that informed consent was not necessary for this retrospective cohort study, and thus patient consent was not obtained.

Provenance and peer review Not commissioned; externally peer reviewed.

Data availability statement Data are available upon request.

Supplemental material This content has been supplied by the author(s). It has not been vetted by BMJ Publishing Group Limited (BMJ) and may not have been peer-reviewed. Any opinions or recommendations discussed are solely those of the author(s) and are not endorsed by BMJ. BMJ disclaims all liability and responsibility arising from any reliance placed on the content. Where the content includes any translated material, BMJ does not warrant the accuracy and reliability of the translations (including but not limited to local regulations, clinical guidelines, terminology, drug names and drug dosages), and is not responsible for any error and/or omissions arising from translation and adaptation or otherwise.

Open access This is an open access article distributed in accordance with the Creative Commons Attribution Non Commercial (CC BY-NC 4.0) license, which permits others to distribute, remix, adapt, build upon this work non-commercially, and license their derivative works on different terms, provided the original work is properly cited, appropriate credit is given, any changes made indicated, and the use is non-commercial. See: <http://creativecommons.org/licenses/by-nc/4.0/>.

ORCID iD

Henry Tout Shu <http://orcid.org/0000-0003-3405-5168>

REFERENCES

- Kaufman EJ, Wiebe DJ, Xiong RA, Morrison CN, Seamon MJ, Delgado MK. Epidemiologic trends in fatal and nonfatal firearm injuries in the US, 2009-2017. *JAMA Intern Med* 2021;181:237-44.
- Long WT, Brien EW, Boucree JB, Filler B, Stark HH, Dorr LD. Management of civilian gunshot injuries to the hip. *Orthop Clin North Am* 1995;26:123-31.
- Zura RD, Bosse MJ. Current treatment of gunshot wounds to the hip and pelvis. *Clin Orthop Relat Res* 2003;408:110-4.
- Bartkiw MJ, Sethi A, Coniglione F, Holland D, Hoard D, Colen R, Tyburski JG, Vaidya R. Civilian gunshot wounds of the hip and pelvis. *J Orthop Trauma* 2010;24:645-52.
- Ho C-J, Hung S-H, Huang H-T, Huang P-J, Lin S-Y, Fu Y-C, Chen J-C, Cheng Y-M, Kang L, Chen C-H. Successful treatment of a delayed presentation of a gunshot injury to the femoral neck in an elderly man: A case report. *Eur J Orthop Surg Traumatol* 2012;22 Suppl 1:131-3.
- Chan H, Chan K, Ip K, *et al*. Open Transcervical fracture of Femur resulted from gunshot injury: a case report. *J Orthop Traum Rehabil* 2018;25:87-90.
- Zhang Y, Wright B, D'Amore P, Hightower C, Stang T, Israel H, Tucker M, Zura R, Cannada LK. Gunshot wounds to the hip: doomed to failure. *J Surg Orthop Adv* 2020;29:135-40.
- Maquingo S, Fegredo D, Brkljac M, Laubscher M. Gunshot wounds to the hip. *J Orthop* 2020;22:530-4.
- Georgiadis GM, Andrews KA, Redfern RE. Gunshot fracture of the femoral neck: internal fixation and immediate proximal femoral Valgus Osteotomy: a case report. *JBJS Case Connect* 2021;11.
- Bell C, Skibicki HE, Post ZD, Ong AC, Ponzio DY. Gunshot wound resulting in femoral neck fracture treated with staged total hip Arthroplasty. *Arthroplast Today* 2022;14:44-7.
- Haidukewych GJ, Rothwell WS, Jacofsky DJ, Torchia ME, Berry DJ. Operative treatment of femoral neck fractures in patients between the ages of fifteen and fifty years. *The Journal of Bone and Joint Surgery-American Volume* 2004;86:1711-6.
- Pauyo T, Drager J, Albers A, Harvey EJ. Management of femoral neck fractures in the young patient: A critical analysis review. *World J Orthop* 2014;5:204-17.
- Collinge CA, Finlay A, Rodriguez-Buitrago A, Beltran MJ, Mitchell PM, Mir HR, Gardner MJ, Archdeacon MT, Tornetta P 3rd, Young Femoral Neck Working Group. Treatment failure in femoral neck fractures in adults less than 50 years of age: analysis of 492 patients repaired at 26 North American trauma centers. *J Orthop Trauma* 2022;36:271-9.
- Collinge CA, Finlay A, Harris P, Rodriguez-Buitrago A, de la Fuente G, Beltran M, Mitchell P, Archdeacon M, Tornetta P 3rd, Mir HR, *et al*. Effects of technical errors on

- the outcomes of Operatively managed femoral neck fractures in adults less than 50 years of age. *J Orthop Trauma* 2023;37:214–21.
- 15 Meinberg EG, Agel J, Roberts CS, Karam MD, Kellam JF. Fracture and dislocation classification Compendium-2018. *J Orthop Trauma* 2018;32 Suppl 1:S1–170.
 - 16 Smolle MA, Leitner L, Böhler N, Seibert F-J, Glehr M, Leithner A. Fracture, Nonunion and postoperative infection risk in the smoking Orthopaedic patient: a systematic review and meta-analysis. *EFORT Open Reviews* 2021;6:1006–19.
 - 17 Pearson RG, Clement RGE, Edwards KL, Scammell BE. Do Smokers have greater risk of delayed and non-union after fracture, Osteotomy and Arthrodesis? A systematic review with meta-analysis. *BMJ Open* 2016;6:e010303.
 - 18 Jo S, Obey M, Berkes M, et al. Ballistic fractures of the femoral neck: treatment and outcomes. *Orthopaedic Trauma Association Annual Meeting* 2020.
 - 19 Slobogean GP, Sprague SA, Scott T, Bhandari M. Complications following young femoral neck fractures. *Injury* 2015;46:484–91.
 - 20 Zhao D, Wang Z, Cheng L, Tian S, Liu B, Yang L, Ma Z. The significance of evaluating the femoral head blood supply after femoral neck fracture: a new classification for femoral neck fractures. *Orthop Surg* 2022;14:742–9.
 - 21 Müslichler H. Arteriographic studies in fractures of the femoral neck and Trochanteric region. type and incidence of findings in Pre- and postoperative examinations, relation to fracture dislocation and Prognostic value. *Angiology* 1970;21:385–402.
 - 22 Rahm S, Hoch A, Tondelli T, Fuchs J, Zingg PO. Revision rate of THA in patients younger than 40 years depends on primary diagnosis – a retrospective analysis with a minimum follow-up of 10 years. *Eur J Orthop Surg Traumatol* 2021;31:1335–44.
 - 23 Pakos EE, Paschos NK, Xenakis TA. Long term outcomes of total hip Arthroplasty in young patients under 30. *Arch Bone Jt Surg* 2014;2:157–62.
 - 24 Deere K, Whitehouse MR, Kunutsor SK, Sayers A, Mason J, Blom AW. How long do revised and multiply revised hip replacements last? A retrospective observational study of the National joint Registry. *The Lancet Rheumatology* 2022;4:e468–79.