

Wrong incisions

David V Feliciano Surgery, University of Maryland
School of Medicine, Baltimore,
Maryland, USA

Correspondence to

Dr David V Feliciano;
davidfelicianomd@gmail.com

HISTORY, PATIENT #1

A 27-year-old man suffered a single stab wound to the left supraclavicular space. A pressure dressing applied in the field by the emergency medical service was saturated with dark blood when the patient arrived at the trauma center.

EXAMINATION, PATIENT #1

The patient was agitated and thrashing about. His blood pressure was 70 mm Hg systolic, heart rate was 130 beats/min, and respiratory rate was 25 breaths/min with barely audible breath sounds on the left and normal breath sounds on the right.

As resuscitation with crystalloid solutions and packed red blood cells was performed, an emergency chest X-ray showed a left hemothorax with a mediastinal shift to the right (figure 1). A left thoracostomy tube was inserted, and 1000 mL of dark blood was rapidly evacuated and autotransfused.

OPERATION, PATIENT #1

The patient was transferred to the operating room where, upon induction by the anesthesiologist, his systolic blood pressure decreased to 30 mm Hg. The surgeon chose to make a left supraclavicular incision to follow the track of the stab wound, but continued profound hypotension prompted conversion to a left ‘book’ thoracotomy incision; that is, a partial median sternotomy and left anterolateral thoracotomy in the fourth intercostal space were connected to the left supraclavicular incision. A 4 cm longitudinal laceration with active bleeding was visualized in the left subclavian vein at its junction with the crossover left innominate vein. An initial attempt to control the laceration in the vein was unsuccessful, and the mid-portion of the left clavicle was resected. Because of continuing hypotension, the descending thoracic aorta was cross-clamped. The left subclavian vein was eventually ligated proximally and distally around the laceration, but the patient had a cardiac arrest from intrapleural exsanguination and could not be resuscitated. Intraoperative transfusion included 34 units of packed red blood cells, 12 units of whole blood, and 12 units of fresh frozen plasma (NOTE: patient’s injury occurred before massive transfusion protocols and ‘1:1:1’ resuscitation were developed).

HISTORY, PATIENT #2

A 22-year-old suffered gunshot wounds two times to the left anterior neck and left hemithorax. He was noted to be moribund by the emergency medical service.

EXAMINATION, PATIENT #2

The patient’s systolic blood pressure was 65 mm Hg, heart rate was 120 beats/min, and respiratory rate was 25 breaths/min with barely audible breath sounds on the left and normal breath sounds on the right. In addition, he was noted to have left anterior cervical and left axillary hematomas and no sensory or motor activity in the left upper extremity. As resuscitation with crystalloid solutions and packed red blood cells was performed, an emergency chest X-ray showed a large left hemothorax (figure 2).

OPERATION, PATIENT #2

The patient was transferred to the operating room. The surgeon chose to make a left supraclavicular incision to expose the left subclavian artery. Proximal control of the left common carotid and subclavian arteries was obtained, and this was followed by performing a left infraclavicular incision to obtain control of the proximal left axillary artery and distal left axillary vein. At this point, the anesthesiologist noted that the patient had a marked decrease in pulmonary compliance and deteriorating arterial blood gases. A left thoracostomy tube was inserted, and 700 mL of blood was rapidly evacuated. Because of persistent hemorrhage and continuing difficulties with ventilation, a partial median sternotomy and left anterolateral thoracotomy in the fourth intercostal space were performed to complete the left ‘book’ thoracotomy. A gunshot wound to the left upper lobe was rapidly oversewn, and the left clavicle was divided at its midpoint. Significant injuries to the second portion of the left subclavian artery and the adjacent left subclavian vein were finally visualized and were noted to be actively bleeding. The injury to the vein was repaired with a continuous polypropylene suture, whereas the artery was ligated proximally and distally around the area of injury. At this point, the patient had an asystolic cardiac arrest which prompted a left pericardiotomy and internal cardiac massage. No cardiac activity was noted, and the patient was pronounced dead from intrapleural exsanguination. Intraoperative transfusion included 24 units of packed red blood cells and 6 units of packed red blood cells from the autotransfuser (NOTE: patient’s injury occurred before massive transfusion protocols and ‘1:1:1’ resuscitation were developed).

DISCUSSION

Injuries to the subclavian vessels were present in 168 (3.2%) of the 5207 patients with vascular injuries in the epidemiological report from Ben Taub Hospital (formerly, Ben Taub General Hospital)/Baylor College of Medicine in Houston, Texas, USA from 1958 to 1988.¹ An overlapping (1955–1978)

© Author(s) (or their employer(s)) 2022. Re-use permitted under CC BY-NC. No commercial re-use. See rights and permissions. Published by BMJ.

To cite: Feliciano DV. *Trauma Surg Acute Care Open* 2022;**7**:e000935.

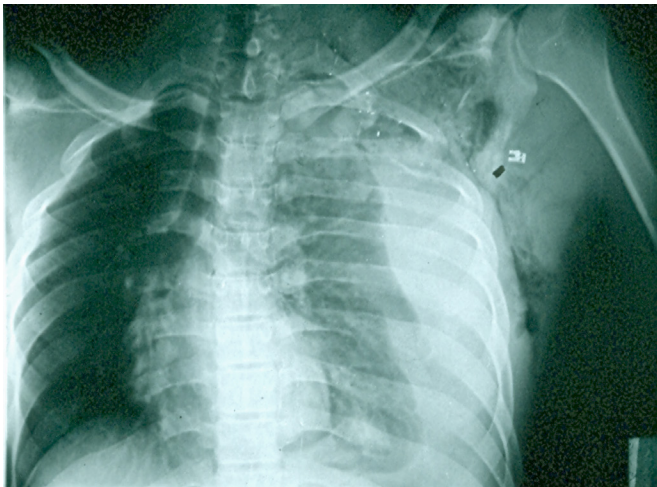


Figure 1 Admission chest X-ray for patient #1 with stab wound to the left supraclavicular space.

and more granular report from the same hospital in 1980 described management and outcome of 93 patients with subclavian vascular injuries.² Of interest, these articles continue to be the largest single-center reports on open management of injuries to the subclavian vessels in the American literature.

The low number of injuries even in a busy urban center with 25% to 30% penetrating trauma at the time and similar experiences in all trauma centers over time speaks to the limited clinical experience any trauma surgeon will have with such injuries. A further decrease in open operative experience for trauma to the subclavian vessels has obviously been due to the application of endovascular stents and stent grafts in reasonably stable patients with intimal defects, pulsatile hematomas (early traumatic false aneurysms), transections, and arteriovenous fistulas. First reported for traumatic injuries to the subclavian artery by Marin *et al* in 1993 and Parodi *et al* in 1999, there is now a large clinical experience with endovascular approaches.³⁻⁷ In addition, there is consensus on the best approaches for these injuries—namely, antegrade wire and stent graft; rendezvous and stent graft; and internal/external rendezvous and stent graft.⁸

These factors have contributed to the current ‘urban legend or implication’ that most injuries to the subclavian vessels can

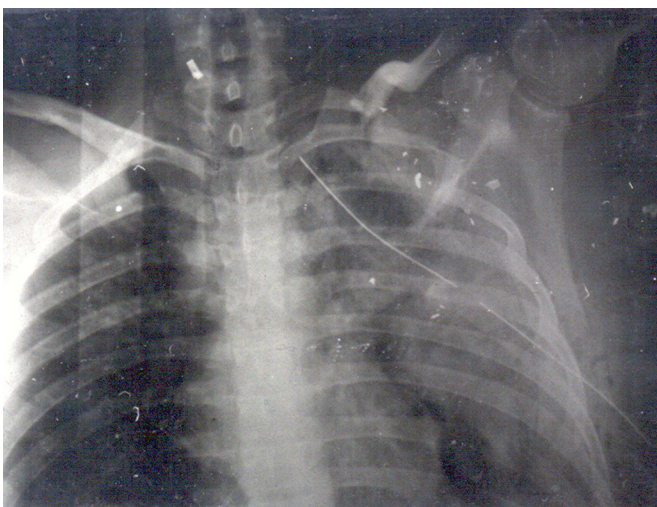


Figure 2 Admission chest X-ray for patient #2 with gunshot wounds to the left anterior neck and left hemithorax.

be managed with endovascular techniques.⁶⁻¹⁰ In a patient with external or intrapleural bleeding from a traumatic injury to a subclavian artery or vein, this would entail percutaneous or retrograde or antegrade passage of an occluding balloon in a patient with hypotension followed by transfusion and insertion of an endovascular stent graft. Obvious requirement for such an approach would include the immediate availability of a trauma vascular surgeon or vascular surgeon trained in these techniques and a hybrid operating room.¹¹⁻¹³

Both patients described in this report were profoundly hypotensive at admission from bleeding due to a penetrating injury to the subclavian vessels. The large volume outputs from their thoracostomy tubes (inexplicably delayed insertion in patient #2) should have confirmed that intrapleural exsanguination was occurring. In patients with this presentation, percutaneous insertion of an inflatable balloon for tamponade or a ‘high’ (fourth intercostal space) anterolateral thoracotomy with manual or laparotomy pad compression of the apex of the pleural cavity is required.¹⁴ This would hopefully tamponade bleeding from the second or third portion of the injured subclavian artery and/or vein. Traditionally, proximal and distal vascular control would then be obtained through the classic supraclavicular incision or, on rare occasions, a book thoracotomy.

Chronically stated reasons not to use open approaches for injuries to the subclavian vessels include the following: (1) time to complete exposure; (2) risk of injury to brachial plexus during exposure; and (3) risk of postoperative infection in the sternum and/or resected or divided clavicle.¹⁰ Concern #1 is true, and this is exactly why a percutaneous balloon is inserted or a thoracotomy for tamponade is performed first in the patient with hypotension with external or intrapleural hemorrhage. Concerns #2 and #3 rarely occur. In the author’s own 40-year clinical experience, there have been no sternal nor clavicular infections and only one injury to the brachial plexus (inadvertent temporary application of vascular clamp rather than transection).

Is there a role for a ‘hybrid’ approach in patients with near-exsanguination from intrapleural hemorrhage from trauma to a subclavian vessel? Absolutely, if the bleeding can be controlled by the aforementioned techniques, then endovascular techniques can be applied in the right setting and with the right support.

One of the major differences between open repairs of vascular trauma and newer endovascular approaches is that there have always been reports on long-term results with the former,¹⁵⁻¹⁹ but uncommonly with the latter.^{6,7} It can be argued that the length of time since the original reports on endovascular repairs in vascular trauma is too short to allow for meaningful follow-up. But, a recent published report based on the National Readmission Database from 2011 to 2014 documented that endovascular repairs for peripheral arterial injuries were ‘associated with higher rates of in-hospital complications, readmissions, and costs’; so, isn’t it time for follow-up for this subset and others of endovascular interventions?²⁰

CONCLUSION

The choice for incision in a patient with hypotension with impending intrapleural exsanguination from an injury to a subclavian vessel is a high anterior thoracotomy when percutaneous balloon tamponade cannot be accomplished or when an endovascular surgeon is not immediately available. Trauma surgeons on call when patients with near-exsanguination from these injuries arrive still need to know open exposures and techniques for repair of these vessels.

Funding The authors have not declared a specific grant for this research from any funding agency in the public, commercial or not-for-profit sectors.

Competing interests None declared.

Patient consent for publication Not required.

Ethics approval Not applicable.

Provenance and peer review Commissioned; internally peer reviewed.

Open access This is an open access article distributed in accordance with the Creative Commons Attribution Non Commercial (CC BY-NC 4.0) license, which permits others to distribute, remix, adapt, build upon this work non-commercially, and license their derivative works on different terms, provided the original work is properly cited, appropriate credit is given, any changes made indicated, and the use is non-commercial. See: <http://creativecommons.org/licenses/by-nc/4.0/>.

ORCID iD

David V Feliciano <http://orcid.org/0000-0001-6923-4639>

REFERENCES

- Mattox KL, Feliciano DV, Burch J, Beall AC, Jordan GL, De Bakey ME. Five thousand seven hundred sixty cardiovascular injuries in 4459 patients. epidemiologic evolution 1958 to 1987. *Ann Surg* 1989;209:698–707.
- Graham JM, Feliciano DV, Mattox KL, Beall AC, DeBakey ME. Management of subclavian vascular injuries. *J Trauma* 1980;20:537–44.
- Marin ML, Veith FJ, Cynamon J, Sanchez LA, Lyon RT, Levine BA, Bakal CW, Suggs WD, Wengerter KR, Rivers SP. Initial experience with transluminally placed endovascular grafts for the treatment of complex vascular lesions. *Ann Surg* 1995;222:449–69.
- Parodi JC, Schönholz C, Ferreira LM, Bergan J. Endovascular stent-graft treatment of traumatic arterial lesions. *Ann Vasc Surg* 1999;13:121–9.
- Xenos ES, Freeman M, Stevens S, Cassada D, Pacanowski J, Goldman M. Covered stents for injuries of subclavian and axillary arteries. *J Vasc Surg* 2003;38:451–4.
- du Toit DF, Lambrechts AV, Stark H, Warren BL. Long-term results of stent graft treatment of subclavian artery injuries: management of choice for stable patients? *J Vasc Surg* 2008;47:739–43.
- Branco BC, Boutrous ML, DuBose JJ, Leake SS, Charlton-Ouw K, Rhee P, Mills JL, Azizzadeh A. Outcome comparison between open and endovascular management of axillosubclavian arterial injuries. *J Vasc Surg* 2016;63:702–9.
- Jinadasa SP, Stoner JF, DuBose JJ, Kundi R, Scalea TM, Morrison JJ. Endovascular management of axillosubclavian artery injuries. *J Trauma Acute Care Surg* 2022;92:e28–34.
- DuBose JJ, Rajani R, Gilani R, Arthurs ZA, Morrison JJ, Clouse WD, Rasmussen TE, . Endovascular Skills for Trauma and Resuscitative Surgery Working Group. Endovascular management of axillo-subclavian arterial injury: a review of published experience. *Injury* 2012;43:1785–92.
- Zambetti BR, Stuber JD, Patel DD, Lewis RH, Huang D-D, Zickler WP, Fischer PE, Magnotti AL, Croce MA, Magnotti LJ. Impact of endovascular stenting on outcomes in patients with traumatic subclavian artery injury. *J Am Coll Surg* 2022;234:444–9.
- Herrold JA, Adnan S, Romagnoli A, Madurska MJ, Betzold R, DuBose J, Scalea T, Morrison JJ. Certification in endovascular hemostasis for trauma surgeons: possible and practical? *J Trauma Acute Care Surg* 2021;91:775–80.
- Harfouche M, Abdou H, Adnan SM, Romagnoli AN, Martinson JR, Madurska MJ, Dubose JJ, Scalea TM, Morrison JJ. Integrating endovascular and operative intervention in trauma. *J Surg Res* 2021;267:82–90.
- Smith BK, Sheahan MG, Sgroi M, Weis T, Singh N, Rigberg D, Coleman DM, Lee JT, Shames ML, Mitchell EL. Addressing contemporary management of vascular trauma: optimization of patient care through collaboration. *Ann Surg* 2021;273:e171–2.
- Feliciano DV. Balloons are not just for children. *Trauma Surg Acute Care Open* 2021;6:e000808.
- McCready RA, Logan NM, Daugherty ME, Mattingly SS, Crocker C, Hyde GL. Long-term results with autogenous tissue repair of traumatic extremity vascular injuries. *Ann Surg* 1987;206:804–8.
- Mitchell FL, Thal ER. Results of venous interposition grafts in arterial injuries. *J Trauma* 1990;30:336–9.
- Shackford SR, Kahl JE, Calvo RY, Shackford MC, Danos LA, Davis JW, Verduyse GA, Feliciano DV, Moore EE, Moore HB, et al. Limb salvage after complex repairs of extremity arterial injuries is independent of surgical specialty training. *J Trauma Acute Care Surg* 2013;74:716–24.
- Klocker J, Bertoldi A, Benda B, Pellegrini L, Gorny O, Fraedrich G. Outcome after interposition of vein grafts for arterial repair of extremity injuries in civilians. *J Vasc Surg* 2014;59:1633–7.
- Feliciano DV, Kochuba MP, Rozycki GF. Review article: history of venous trauma. *J Trauma Acute Care Surg* 2021;91:e62–72.
- Asmar S, Bible L, Obaid O, Tang A, Khurram M, Castanon L, Ditillo M, Joseph B. Open vs endovascular treatment of traumatic peripheral arterial injury: propensity matched analysis. *J Am Coll Surg* 2021;233:131–8.