

Endovascular stent graft repair of an abdominal gunshot with liver and aortic injuries

Natesh Yepuri, Michael Costanza, Alex Helkin, Robert N Cooney

Department of Surgery, SUNY Upstate Medical University, Syracuse, New York, USA

Correspondence to

Dr. Robert N Cooney,
Department of Surgery Upstate Medical University, 750 E. Adams St, Suite 8141 Syracuse, NY 13210, USA; CooneyR@upstate.edu

Received 9 June 2017
Revised 13 June 2017
Accepted 13 June 2017

After being shot in the abdomen with a small caliber gun, a 16-year-old boy was transported to the emergency department (ED) in a private vehicle. On arrival to the ED, he was pale, tachycardic, and hypotensive. Intravenous access was obtained, and 1 L of saline and 2 units of packed red blood cells were given to stabilize the patient. Abdominal examination showed a subxiphoid entrance wound with no signs of peritonitis. No exit wound or other significant physical examination findings were noted. Focused Assessment with Sonography for Trauma (FAST) examination was negative for pericardial fluid but positive for minimal intra-abdominal fluid. Chest radiograph was negative for hemothorax and pneumothorax.

His vital signs remained stable so he was taken for CT imaging. CT scan (figure 1) showed a linear laceration of the left hepatic lobe with the bullet trajectory passing through the supraceliac aorta. Irregularity of the aortic wall and extensive retroperitoneal hemorrhage surrounding the aorta were concerning for aortic injury, but no contrast extravasation was noted. A L1 vertebral body fracture was seen and the bullet lodged in the left paraspinal soft tissues.

WHAT WOULD YOU DO?

- Abdominal exploration with medial visceral rotation and aortic repair?
- Femoral artery access followed by exploratory laparotomy and endovascular stent graft (ESG) repair?
- Aortic repair with interposition bypass graft? or
- Laparotomy repair of liver with delayed repair of aorta?

WHAT WE DID AND WHY

Correct answer: B

We started by obtaining left femoral artery access, then placed a 12 Fr sheath and aortic guide wire to facilitate balloon occlusion if needed. Then exploratory laparotomy was performed to assess the liver and rule out associated intra-abdominal injuries. Hemostasis of the liver was obtained and the bullet passed medial to the lesser curve of the stomach into the retroperitoneum and through the aorta. The patient's vitals were normal, no other visceral injuries were noted, and the peri-aortic hematoma was not expanding. Instead of performing a medial visceral rotation to expose and repair the aorta, an aortogram was performed and the location of the injury and the origins of the celiac artery were confirmed. A supraceliac aortic stent graft (figure 2) was placed to repair the injury, then the abdomen was closed. The postoperative course was

uneventful and the patient was discharged on the second postoperative day.

Penetrating aortic injuries (PAI) are uncommon and frequently lethal with <10% of patients reaching the hospital alive. Those with major retroperitoneal hemorrhage have a mortality rate of 1% per hour during the first 48 hours. The principal determinants of death in PAI are hemodynamic status, injury mechanism, status of clot, and degree of hemorrhage during surgery. Patients with PAI are often hemodynamically unstable on arrival. In this patient, a low-velocity weapon caused a through and through aortic injury with a contained peri-aortic hematoma. Although the patient was not actively bleeding, hemostasis could be transient and unpredictable in duration. Immediate abdominal exploration with medial visceral rotation for exposure and repair involves more extensive surgery and can result in massive hemorrhage or additional injury. Since the natural history of this injury is unclear, delayed aortic repair or nonoperative observation risks delayed pseudoaneurysm development or rupture from clot lysis.

Surgical options for PAI of the supraceliac aorta include primary repair or interposition bypass through a thoracoabdominal exposure. The disadvantages of open surgery include significant mortality and morbidity including potential paraplegia. Endovascular therapy (ET) for PAI has the potential advantage of minimizing blood loss, decreasing operating time, and avoiding the morbidity associated with thoracoabdominal exposure and aortic clamping. ET may provide definitive repair or serve as a bridge until the patient is stable enough to undergo open surgery.

This case describes successful endovascular repair of a penetrating injury to the liver and

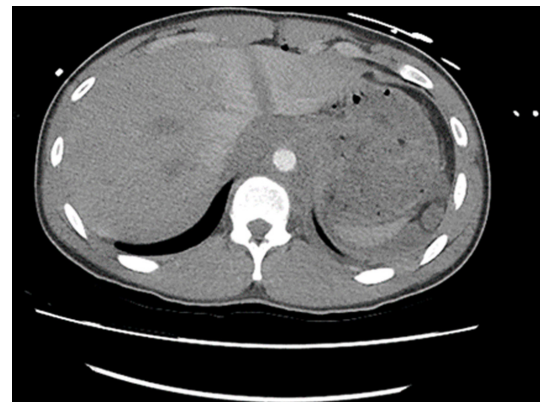

Figure 1 CT scan with liver laceration and peri-aortic hematoma.

To cite: Yepuri N, Costanza M, Helkin A, et al. *Trauma Surg Acute Care Open* 2017;2:1–2.

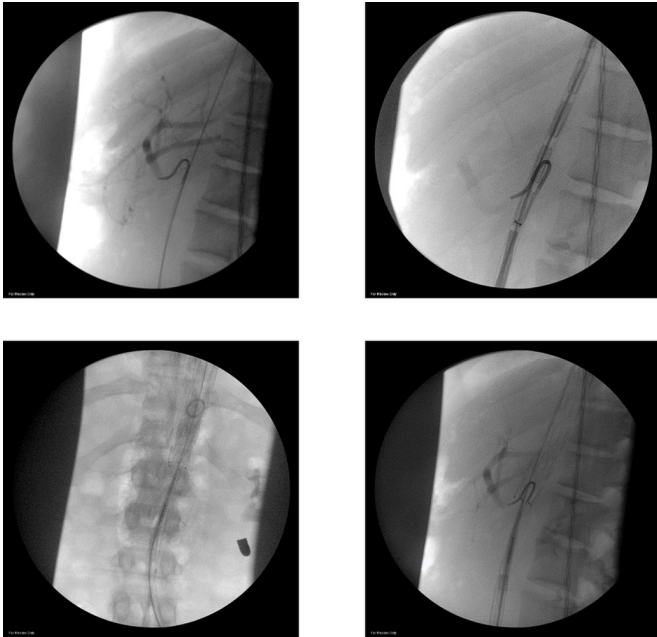


Figure 2 Aortogram—the level of the celiac artery was identified and cannulated. The graft was deployed using the catheter in the celiac artery as a guide.

supraceliac aorta. Placing an aortic stent graft in a young patient raises the question of stent graft durability and regular surveillance will be an important part of this patient's long-term follow-up. In general, ET for traumatic injuries should be used judiciously and ideally reserved for patients in need of expeditious repair for injuries in difficult-to-expose locations. In conclusion, ET appears to be a reasonable and effective technique for repair of supraceliac (PAI). The advantages of ET in this patient include minimal blood loss, decreased operative time, and avoiding the need for thoracoabdominal exposure and aortic clamping.

Contributors NY was involved in writing the manuscript. NY and AH conducted literature search. RNC and MC were involved in surgical management of the patient. RNC and MC carried out the critical revision of the manuscript.

Competing interests None declared.

Provenance and peer review Not commissioned; externally peer reviewed.

Open Access This is an Open Access article distributed in accordance with the Creative Commons Attribution Non Commercial (CC BY-NC 4.0) license, which permits others to distribute, remix, adapt, build upon this work non-commercially, and license their derivative works on different terms, provided the original work is properly cited and the use is non-commercial. See: <http://creativecommons.org/licenses/by-nc/4.0/>

© Article author(s) (or their employer(s) unless otherwise stated in the text of the article) 2017. All rights reserved. No commercial use is permitted unless otherwise expressly granted.