

# Penetrating chest injury secondary to an improvised home-made marble airgun: a case report

John Kristoffer Manicani Japzon , Halima O Mokamad-Romancap

Department of Surgery,  
Cotabato Regional and  
Medical Center, Cotabato City,  
Philippines

## Correspondence to

Dr John Kristoffer Manicani  
Japzon; jkijapzon@gmail.com

## ABSTRACT

**Background** An improvised air gun with marble bullets, locally known as "Jolen Gun", is a type of home-made gun using Polyvinyl chloride (PVC) pipes and compressed air. It is mainly being used as a hunting tool in Central Mindanao. This "non-lethal" weapon has the potential in causing serious harm. There has been several incidents of minor injuries from this type of weapon in our institution but this is the first documented case of an improvised marble air-gun causing significant injury to the patient.

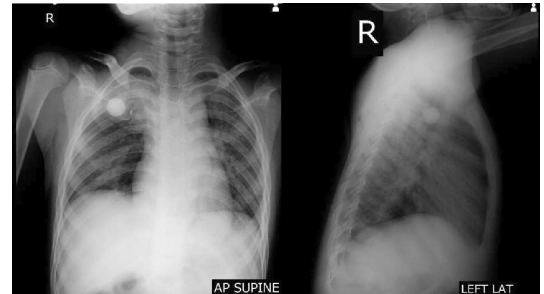
**Case report** A child was brought to a rural tertiary center after being shot in the chest using an improvised gun with marble as bullet. On evaluation, the patient had a single gunshot wound approximately 2 cm x 2 cm in size on the posterior chest at the right paravertebral area of the 4th thoracic vertebra. There was no exit wound noted. Chest CT done showed a rounded radiopaque foreign body seen in the right upper lung field with gunshot fracture involving the posterior aspect of the 4th rib. There was also pulmonary contusion of the right upper lobe and a fluid density at the right posterior pleural space attributed to a hemothorax. Open thoracotomy, removal of foreign body, repair of lung injury and debridement was done. Patient had an unremarkable post-operative course and was subsequently discharged.

**Conclusion** After extensive search of both local and international literatures, this appears to be the first case involving a penetrating chest injury from an improvised marble air-gun which has been treated successfully. Although this is a low-energy type of weapon, it still has the potential to cause significant harm to the body. Relevant laws should be made to against the use of this type of weapon to prevent similar injuries in the future.

## CASE REPORT

A child was brought to a rural tertiary center after being shot in the chest with an improvised gun with marble as a bullet. He appeared to be awake, not in respiratory distress, and had stable vital signs. On evaluation, the patient had a single gunshot wound approximately 2x2 cm in size on the posterior chest at the right paravertebral area of the fourth thoracic vertebra. There was no exit wound noted. Auscultation revealed a slight decrease in breath sounds at the right upper lung field. Initial chest radiograph was done revealing a round radiopaque material which was thought to be a foreign body (marble) at the right upper lung, with fracture of the fourth posterior rib ([figure 1](#)). There was no hemothorax or pneumothorax noted.

The patient was admitted and a repeat chest radiograph was taken after 6 hours ([figure 2](#)). A

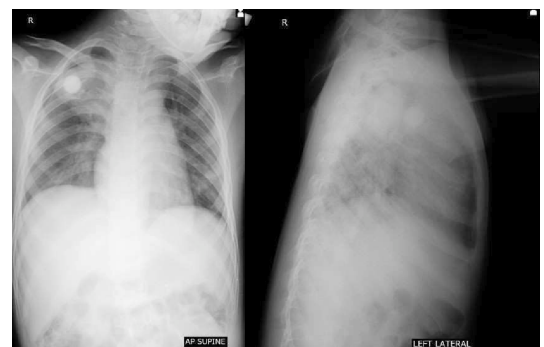


**Figure 1** Initial chest radiograph at the emergency room. Round radiopaque material which was thought to be a foreign body (marble) at the right upper lung, with fracture of the fourth posterior rib. AP, anteroposterior; LAT, lateral.

developing pulmonary contusion surrounding the foreign body was noted. The patient was stable enough to permit chest CT evaluation. It showed a rounded radiopaque foreign body in the right upper lung field, with gunshot fracture involving the posterior aspect of the fourth rib. There was also pulmonary contusion on the right upper lobe and a fluid density at the right posterior pleural space attributed to a hemothorax ([figure 3](#)).

The case was referred to a thoracic surgeon consultant. On review of the chest CT scan, it appeared that a fragment of the fourth rib was piercing through the upper lobe of the right lung. Surgery was advised and the patient was scheduled for thoracotomy, removal of foreign body, and debridement.

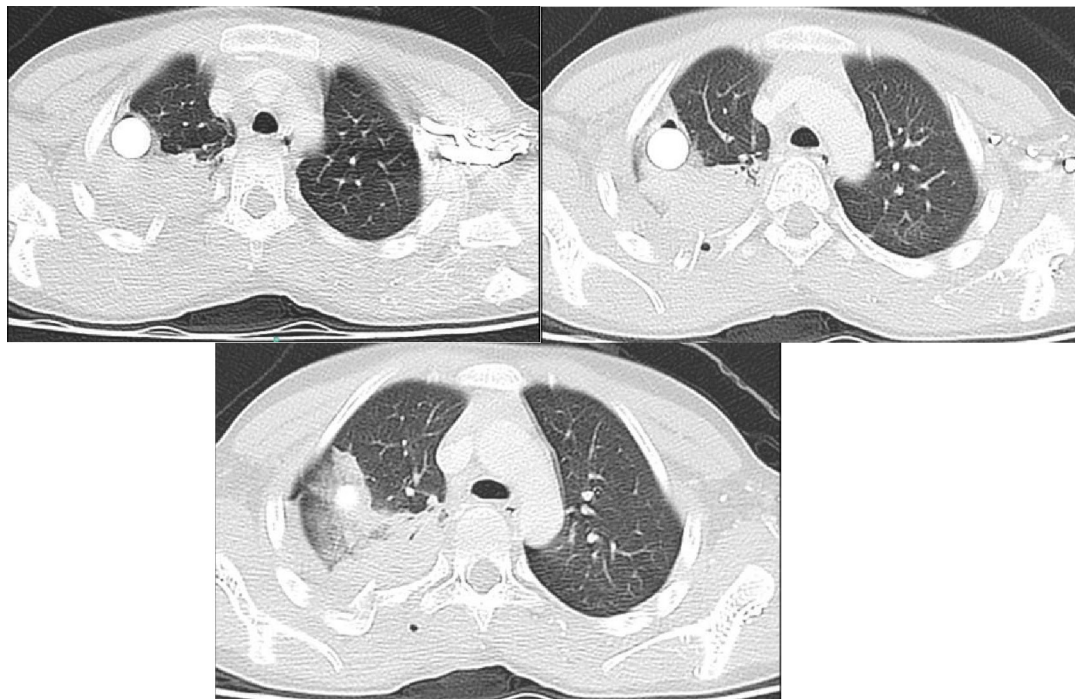
During the operation, a right posterolateral approach was made. The foreign body was identified and removed. Rib fragments were also removed and hemothorax was drained. Repair of the lung injury was done ([figure 4](#)). The surrounding organs were inspected but no injuries were reported. A chest tube



**Figure 2** Repeat radiograph after 6 hours. Developing pulmonary contusion noted. AP, anteroposterior.

© Author(s) (or their employer(s)) 2023. Re-use permitted under CC BY-NC. No commercial re-use. See rights and permissions. Published by BMJ.

**To cite:** Japzon JKM, Mokamad-Romancap HO. *Trauma Surg Acute Care Open* 2023;**8**:e001260.



**Figure 3** Chest CT. Rounded radiopaque foreign body seen in the right upper lung field with gunshot fracture involving the posterior aspect of the fourth rib. There was also pulmonary contusion in the right upper lobe and a fluid density at the right posterior pleural space attributed to a hemothorax.

was left in place prior to closure. He was extubated postoperatively and transferred to the postanesthesia care unit and had an unremarkable stay.

On postoperative day 1 (POD 1), full diet was resumed. The patient was started on incentive spirometry and chest tube output was monitored daily (figure 5). A postoperative chest radiograph was taken noting a full expansion of the lung, without pneumothorax and with the chest tube in place. On POD 4, there was absence of chest tube output. A repeat chest radiograph showed clear and fully expanded

lung (figure 6). After 24 hours of observation, the chest tube was removed. He was discharged on the seventh POD. At the time of discharge, he had full functional capacity, without oxygen support or any assistive device.

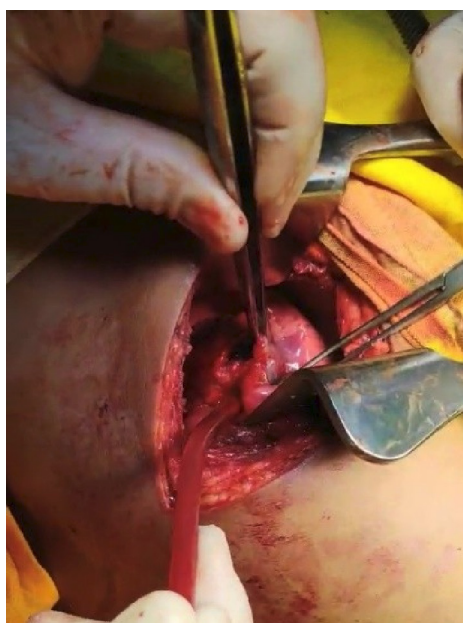One week after discharge, the patient reported no difficulty of breathing or chest pain. Repeat radiograph showed a normal study (figure 7). He was already doing mild to moderate strenuous activities without developing dyspnea. He was able to return to school without any limitations.

## DISCUSSION

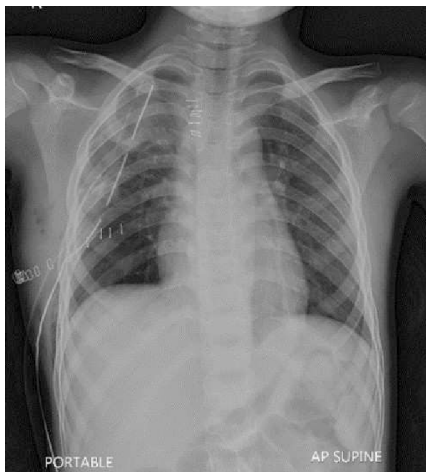“Non-lethal weapons” that use rubber bullets, plastic bullets, or beanbag rounds have been developed for the purpose of helping law enforcement. A case report of a 46-year-old man who had suffered a penetrating chest injury due to beanbag bullet showed the potential of these non-lethal weapons to cause serious harm.<sup>1</sup> In another case, a man died of a chest injury from an air rifle with diabolo pellet after penetrating the right ventricle of the heart and subsequently entering the vasculature of the left lung.<sup>2</sup> In some parts of Central Mindanao, an improvised version of these non-lethal weapons was developed. An improvised airgun with marble bullets, locally known as “jolen gun,” is a type of home-made gun that uses polyvinyl chloride pipes and compressed air. It is mainly used as a hunting tool in Central Mindanao and sometimes for protection of livestock such as goats from other animals. Occasionally, it is being used as children’s toy.

Although there are no published reports, there have been several incidents of marble gun injury causing minor lacerations presenting to the emergency department. However, after extensive search of both local and international literatures, this appears to be the first case involving a penetrating chest injury from an improvised marble airgun that has been treated successfully and subsequently discharged.

In one retrospective study, the most common mechanism of chest trauma was motor vehicular crash (42%), with



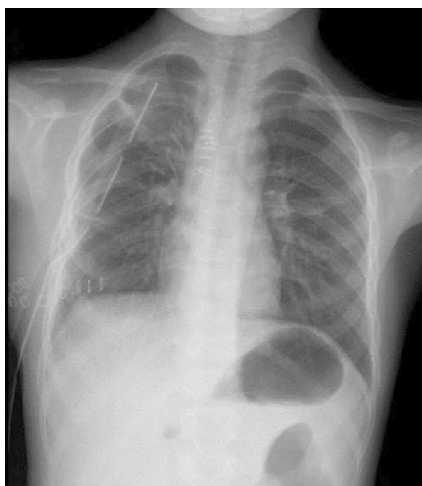
**Figure 4** Intraoperative image showing the marble perforating the lung parenchyma.



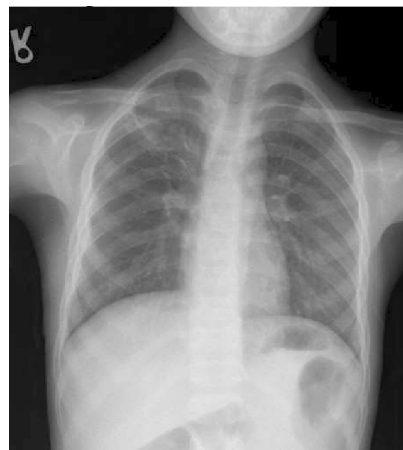**Figure 5** Postoperative day 1 radiograph. Shown is a fully expanded lung without pneumothorax. AP, anteroposterior.

assault only representing 5.8% of cases, and with elective or emergent surgery only being performed in 23.4% of patients.<sup>3</sup> Penetrating thoracic trauma from gunshot wound appears to have a higher mortality rate (52%) compared with stab wounds (30%).<sup>4</sup> The critical condition of thoracic trauma patients makes the surgical management challenging for general surgeons, who mostly have general knowledge of basic cardiothoracic operations.<sup>5</sup>

Because the patient was in a stable condition, available diagnostic imaging tools (X-rays and CT) were used to help in the preoperative planning of the surgery. Although bullet entry and exit wounds are easily identified during physical examination, the path and the damage caused within the tissues are not apparent; hence, it is advised that, in hemodynamically stable gunshot patients, thoracoabdominal CT be performed for timely and correct diagnosis.<sup>6</sup> Furthermore, multidetector CT may have a superior performance in detecting tissue and organ injuries.<sup>7</sup> With the help of these ancillary tests, a decision was made to perform surgery because of the presence of concomitant rib injury and because the foreign body may cause significant morbidity. In addition, the patient lives in a rural community, which may prevent him from seeking consult early.



**Figure 6** Postoperative day 4. Shown are fully expanded lungs and total regression of pulmonary contusion.



**Figure 7** Chest radiograph on follow-up consult showed a normal study.

Open thoracotomy was done with our case to provide better visualization and assessment of the damage caused by the jolen gun. In addition, because our hospital is a rural tertiary center, we lack the necessary equipment and expertise to do a more advanced and minimally invasive thoracic surgery. It has been reported, however, that in the management of hemodynamically stable thoracic injuries, video-assisted thoracoscopic surgery provides a high diagnostic accuracy and also offers therapeutic intervention with decreased incidence of wound and pulmonary complication, resulting in higher patient satisfaction in terms of rate of return to normal lifestyle.<sup>8</sup>

The degree of injury was less partly because the jolen gun produces a low-velocity bullet, causing lesser degree of tissue damage. Furthermore, as the bullet strikes an object, it slows and energy is transferred to the object. It has been shown that as lungs absorb much of the energy, the parenchyma compresses and rebound, and the bone resists displacement until it shatters.<sup>6</sup> In addition, the available modalities at our center provided us with the necessary information to manage the case effectively. All these factors contributed to the success of the surgery.

Despite being a rural tertiary center, we were able to use all our available resources to effectively manage and treat a child who suffered a penetrating chest trauma due to a jolen gun. As general surgeons, basic knowledge of cardiothoracic surgery is important as we expect more of injuries of the same nature to happen. Relevant laws and policies should also be made by governments to avoid further injuries from these type of non-lethal weapons.

**Contributors** JKMJ and HOM-R conceived the idea of writing an article of a case handled by JKMJ. JKMJ is responsible for the overall content and accepts full responsibility for the conduct of the study, access to data and controlled the decision to publish. HOM-R was responsible for checking and reviewing the final article.

**Funding** The authors have not declared a specific grant for this research from any funding agency in the public, commercial or not-for-profit sectors.

**Competing interests** None declared.

**Patient consent for publication** Not required.

**Provenance and peer review** Not commissioned; internally peer reviewed.

**Open access** This is an open access article distributed in accordance with the Creative Commons Attribution Non Commercial (CC BY-NC 4.0) license, which permits others to distribute, remix, adapt, build upon this work non-commercially, and license their derivative works on different terms, provided the original work is

properly cited, appropriate credit is given, any changes made indicated, and the use is non-commercial. See: <http://creativecommons.org/licenses/by-nc/4.0/>.

#### ORCID iD

John Kristoffer Manicani Japzon <http://orcid.org/0009-0009-4305-1020>

#### REFERENCES

- 1 Thakur S, Teloken PE, Gilfillan I, Sharma S. Penetrating chest injury due to Beanbag bullet. *BMJ Case Rep* 2013;2013:bcr2012008482.
- 2 Mogni B, Maines S. Homicide using an air weapon. *Clin Pract Cases Emerg Med* 2019;3:289–94.
- 3 Zhang S, Tang M, Ma J, Yang J, Qin X, Jin W, Qian J, Li F, Cheng Y, Chen H. Thoracic trauma: a descriptive review of 4168 consecutive cases in East China. *Medicine (Baltimore)* 2019;98:e14993.
- 4 Clarke DL, Quazi MA, Reddy K, Thomson SR. Emergency operation for penetrating thoracic trauma in a metropolitan surgical service in South Africa. *J Thorac Cardiovasc Surg* 2011;142:563–8.
- 5 Degiannis E, Zinn RJ. Pitfalls in penetrating thoracic trauma (lessons we learned the hard way). *Ulus Travma Acil Cerrahi Derg* 2008;14:261–7.
- 6 Karaca MA, Kartal ND, Erbil B, Öztürk E, Kunt MM, Şahin TT, Özmen MM. Evaluation of gunshot wounds in the emergency department. *Ulus Travma Acil Cerrahi Derg* 2015;21:248–55.
- 7 Akgul Ozmen C, Onat S, Aycicek D. Radiologic findings of thoracic trauma. *Ther Clin Risk Manag* 2017;13:1085–9.
- 8 Aljehani Y, Alsafwani E, Alayyaf N. A novel approach in retrieving retained pulmonary bullet injury. *Trauma Case Rep* 2019;21:100191.